JVHS

Research Article

e-ISSN: 2147-7892
dergipark.org.tr/en/pub/inonusaglik

HISTOLOGICAL ASSESSMENT OF IRON DEPOSITION IN BREAST CANCER

Büşra ERKAN, İnönü University, Vocational School of Health Services, Medical Services and Techniques, Malatya, Türkiye

Andrew R GREEN, University of Nottingham, School of Medicine, Nottingham, United Kingdom

Corresponding Author : *Büşra ERKAN, busra.erkan@inonu.edu.tr*

Citation: Erkan, B., & Green, A. R. (2026). Histological assessment of iron deposition in breast cancer. *Journal of İnönü University Health Services Vocational School*, *14*(2), 251–258.

doi 10.33715/inonusaglik.1842489

Received Date: December 15, 2025 / **Accepted Date:** March 18, 2026 / **Published Date:** June 22, 2026

Abstract

In this study, we investigated the spatial distribution of iron in ER+/HER2- tissues using Prussian blue histochemical staining combined with digital pathology analysis. Whole-slide image evaluation revealed marked intratumoural heterogeneity in iron deposition, with focal iron-rich and iron-poor regions frequently observed within the same tumour. In addition, iron accumulation was often detected in peritumoural areas, suggesting a contributory role of the tumour microenvironment in local iron remodelling. Although Prussian blue staining detects ferric iron and does not directly measure ferroptosis, the presence of iron-rich niches may indicate regions with increased vulnerability to iron-dependent oxidative stress. These findings highlight iron dysregulation as a potential contributor to breast cancer heterogeneity and support further investigation ofinto ferroptosis-related pathways in tissue-based studies.

Keywords: Breast cancer, Iron metabolism, Ferroptosis.

İNÖNÜ UNIVERSITY PRESS

Journal of İnönü University Vocational School of Health Services is a peer-reviewed open access journal. © 2026 The Author(s). OPEN ACCESS

INTRODUCTION

Breast cancer (BC) is one of the most common cancers worldwide and the second leading cause of cancer-related deaths in women (World Health Organization (WHO),2022). Its heterogeneous nature makes the development of effective and targeted treatments challenging (Łukasiewicz et al., 2021). Molecular characterisation has classified BC into four main subtypes luminal A, luminal B, HER2+, and triple-negative BC (TNBC) and HER2-enriched (Vidal, Paré & Prat, 2016). Surgery, targeted therapy, chemotherapy, and radiotherapy have improved patient care; yet some BCs remain aggressive and survival rates are low. Many tumours also develop resistance to standard chemotherapies that induce apoptosis (Mellor & Callaghan, 2008). These challenges highlight the need to explore alternative cell death pathways such as ferroptosis and to identify new biomarkers and therapeutic targets that could improve treatment efficacy and patient outcomes.

In recent years, ferroptosis has become a focal point of cancer research as a non-apoptotic, regulated cell death pathway (Ge et al., 2024; Liu, Hu, Jiang, Bu & Gu, 2022). Ferroptosis is defined by morphological alterations and metabolic dependencies that clearly separate it from other forms of regulated cell death, including apoptosis, necroptosis, and pyroptosis (Yan et al., 2021). It is an iron-dependent form of regulated cell death, characterised by the accumulation of intracellular reactive oxygen species (ROS) and distinct from apoptosis and autophagy in both morphology and mechanism (Ding et al., 2025; Yan et al., 2021). The core process involves divalent iron (Fe2+) or ester oxygenases catalysing the peroxidation of polyunsaturated fatty acids in cell membranes, leading to lipid peroxidation and subsequent cell death (Feng et al., 2023). Dysregulation of iron metabolism can promote tumour development, as cancer cells often have higher iron requirements than normal cells. Activation of ferroptosis pathways is considered a promising approach to overcome resistance to conventional chemotherapies, offering new therapeutic opportunities (Dai et al., 2025). Ferroptosis induces metabolic disturbances that generate cytoplasmic and lipid ROS, largely independent of mitochondria but in some contexts dependent on NADPH oxidases (Chen et al., 2024; Dai et al., 2025). For instance, a recent study has utilised Fe2+-based metal-organic frameworks to deliver iron to cancer cells, triggering Fenton reactions, ROS accumulation, and ferroptotic cell death in BC (K. Zhang et al., 2021).

Many cancer-related signalling pathways have been found to play important roles in controlling ferroptosis in cancer cells, including those in colorectal, renal, esophageal, lung, and breast cancers (Yan et al., 2021). Loss or suppression of p53 reduced ferroptosis through increased cystine uptake, suggesting that TP53 functions as a positive regulator of ferroptotic cell death in the BC MCF-7 cell line. Previous studies in BC have shown that SLC7A11 upregulation enhances antioxidant defenses and suppresses ferroptosis, thereby promoting tumour growth (Liu et al., 2024).

Nevertheless, systematic analyses of ferroptosis-related molecular signatures as predictors of overall survival (OS) in BC patients remain limited. The malignant phenotype in breast epithelial cells is strongly linked to disrupted iron homeostasis. Cancerous transformation is accompanied by altered expression of multiple iron-regulating proteins, including key mediators of iron uptake, storage, and export at the cellular level (Marques et al., 2016). Therefore, gaining a deeper understanding of ferroptosis in cancer is essential to support the clinical adoption of ferroptosis-targeted therapeutic strategies and to bridge the current translational gap between experimental studies and patient-oriented applications. In this study, we aimed to characterise the distribution of iron in BC tissues by Prussian blue staining and to discuss the potential implications of iron-rich regions for ferroptosis susceptibility and BC heterogeneity.

MATERIAL AND METHOD

Study Cohort

This study utilised tumour samples from the Nottingham Primary Breast Cancer series, a well-established collection of early-stage, primary, operable, invasive BC cases. 4-μm sections were prepared from formalin-fixed, paraffin-embedded (FFPE) blocks of ER+/HER2- BC cases (n=20).

Prussian Blue Staining

Prussian blue staining was performed to detect cellular iron accumulation. Spleen tissue was included as a positive control, and normal breast tissue as a negative control. Sections were deparaffinised and rehydrated in graded ethanol and rinsed in distilled water. A working iron-stain solution was prepared by mixing equal volumes of potassium ferrocyanide and hydrochloric acid (Iron Stain Kit, ab150674, Abcam, Cambridge, UK). Slides were incubated in the working solution for 3 min and rinsed thoroughly in distilled water. Nuclei were counterstained with Nuclear Fast Red (manufacturer) for 5 min, rinsed in four changes of distilled water, dehydrated in 95% ethanol followed by absolute ethanol, cleared, and mounted.

Digital Imaging

Stained tissue sections were digitized as high-resolution images using a NanoZoomer (Hamamatsu Photonics, UK) at 20x magnification and viewed with NDP.view2 (Hamamatsu Photonics, UK). The analysis was performed at very high resolution (0.88 μm/pixel), allowing detailed visualisation of cellular morphology and iron deposition patterns. Cell nuclei are visualised in pink, and ferric iron deposits are highlighted in bright blue.

ROI Identification and Tissue Quality Assessment

Staining evaluation and visual assessment of tissue were performed using QuPath software. Regions of interest (ROIs) were manually delineated using drawing tools, and each selected region underwent careful quality assessment. Tissue areas exhibiting tearing, folding, necrosis, uneven staining, or other artefacts were excluded. Tissue integrity was evaluated at both low (4x-10x) and high (20x-40x) magnifications. Low magnification allowed a rapid overview of general tissue architecture and identification of potential ROIs, whereas high magnification was used to confirm cellular morphology, chromogen localisation, and adequate signal-to-background contrast.

Tumour and Stroma Selection

Stromal regions were systematically excluded, and only tumour areas with clear morphology and optimal staining were included in the analysis. In cases where different stainings displayed varying levels of structural integrity, a standardised two-step selection workflow was applied, consisting of an initial low-magnification overview to identify candidate ROIs, followed by high-magnification refinement to finalise the selections.

Staining Annotation

Within the finalised ROIs, subregions showing distinct staining characteristics were annotated for detailed assessment. Each stain was assigned to a separate colour channel within QuPath, enabling clear differentiation and facilitating subsequent analysis.

RESULT

After Prussian blue staining, all slides were scanned using a digital slide scanner (NanoZoomer, Hamamatsu, Japan) in NDP format at 10x and 20x magnification. Tumour regions of interest (ROIs) were delineated across the entire tissue section by outlining areas composed of tumour cells. Representative tumour regions exhibiting both positive and negative iron staining, together with adjacent stromal areas, were manually annotated to generate training data for image analysis in Figure 1. Following training, the classification algorithm was applied to whole-slide images to evaluate its performance. Misclassified regions were identified and corrected through iterative retraining or manual adjustment, thereby improving classification accuracy. Figures 1A–C illustrate the original stained tissue and demonstrate pronounced intratumoural heterogeneity, with areas of both high (dark blue) and low (light blue) iron accumulation within the same tumour region. Figure 1B-D show the corresponding analysed images following algorithm training, in which tumour regions and iron-positive areas are clearly delineated.

Analysis of iron accumulation showed positive staining in only 4 of 20 ER+/HER2- BC cases. The highest percentage of iron-positive tumour cells was 16%, and the lowest was 5%. In the remaining 16 cases, no detectable iron deposition was observed within tumour regions. Overall, no consistent pattern of intratumoural or peritumoural iron accumulation was identified across the cohort, suggesting that iron deposition in ER+/HER2- breast tumours is sporadic and highly variable among cases.

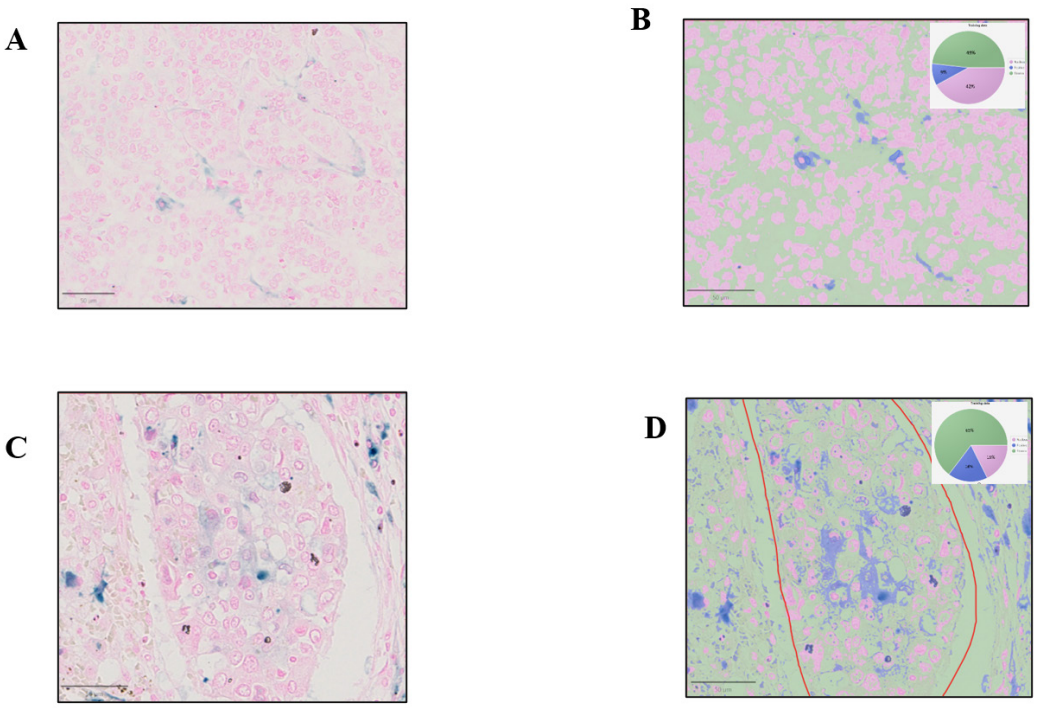

Figure 1: Digital image analysis for the assessment of iron deposition in breast cancer tissue. A–C) Representative whole-slide images of breast cancer tissue sections stained with Prussian blue. B–D) Corresponding QuPath-based digital analysis outputs following algorithm training. Iron-positive nuclei and stromal regions are automatically detected and highlighted within the defined regions of interest(ROIs).Quantification was performed based on the percentage of iron-positive area and staining intensity. Scale bars: 50 µm and original magnification 20x.

Figure 2 includes spleen tissue (Figure 2A) as a positive control, demonstrating robust ferric iron staining, and normal breast tissue (Figure 2B) as a negative control, exhibiting minimal to no detectable iron deposition.

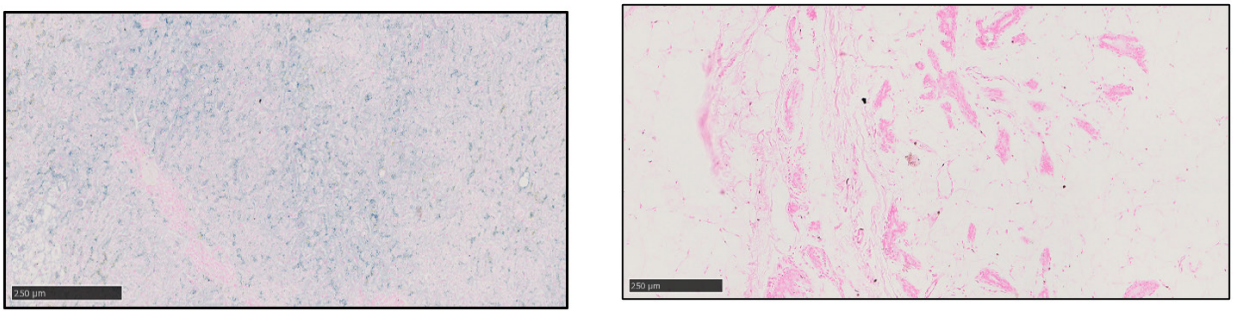

Figure 2: Positive and negative control tissues for Prussian blue staining. A) Spleen tissue was used as a positive control to verify the presence of iron deposition B) Normal breast tissue was used as a negative control to confirm the absence of Prussian blue staining.

BBAA Figure 3A–B illustrates the distribution of iron (blue) in breast cancer tissue, showing predominant accumulation in peritumoral regions. Iron deposition was markedly higher in the stromal tissue surrounding the tumor than in the intratumoral compartment.

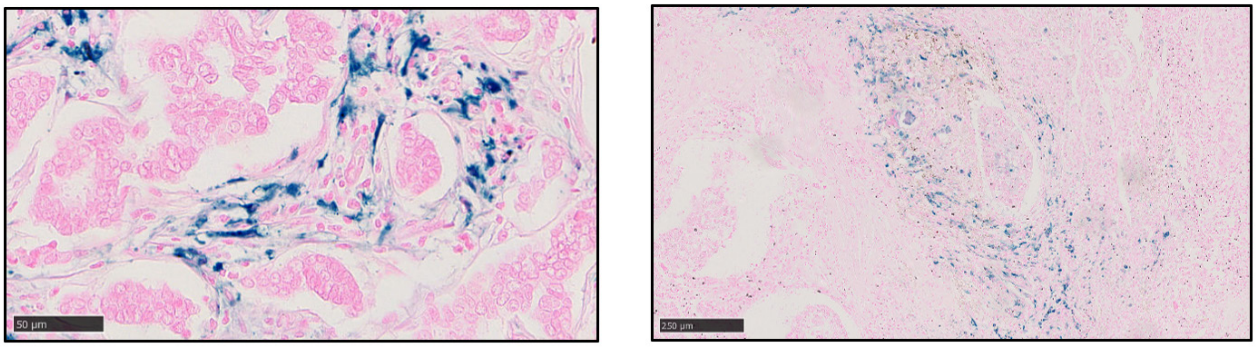

Figure 3: Iron accumulation in peritumoural regions of breast cancer tissue. A-B) Iron deposits, visualised by bright blue staining, are predominantly localised to the peritumoural regions. Scale bars: 50 µm and 250 µm respectively.

DISCUSSION

Breast cancer (BC) remains a major global health burden and is characterised by substantial biological, molecular and clinical diversity. This heterogeneity underlies the wide variation observed in tumour behaviour, treatment response, and patient outcomes (Carroll et al., 2008; Łukasiewicz et al., 2021). Differences in hormone receptor status, growth factor expression, metabolic reprogramming, and tumour microenvironment collectively shape the complex landscape of BC, often contributing to therapeutic resistance and disease progression (Liu et al., 2024; Mao, Xia, Xia, & Jiang, 2024). Increasing evidence suggests that alterations in iron metabolism and susceptibility to ferroptosis an iron-dependent form of regulated cell death represent additional layers of heterogeneity that influence tumour biology and treatment response (Dai et al., 2025). Ferroptosis has emerged as a critical pathway affecting metabolic vulnerabilities and therapeutic sensitivity, positioning iron handling as a promising area for biomarker discovery and targeted intervention (Liu et al., 2022).

Prussian blue staining reflects static iron accumulation rather than active ferroptotic processes, the presence of iron-rich regions may indicate microenvironments where excess iron could facilitate lipid peroxidation and increase ferroptosis susceptibility (Sonoda, Nihei, Shinkawa, Kakizaki & Yukawa, 2025). Thus, limited Fe^{3+} deposition does not exclude ferroptotic potential. This can provide a conceptual link between iron deposition patterns and potential ferroptotic vulnerability within tumours. Although this method does not directly measure the labile Fe^{2+} pool that drives ferroptosis, it can indicate regions with altered iron handling. More specific detection of ferroptotic activity relies on immunohistochemical markers, such as 4-HNE and MDA (for lipid peroxidation), loss of GPX4, or upregulation of ACSL4. Functional evidence of iron-dependent vulnerability can be inferred by applying iron chelators such as deferoxamine in experimental tissue models to determine whether ferroptosis-like changes are iron-dependent (Thi Nghiem et al., 2025; Zhang, Liu, Liao, Zhu, & Zou, 2024). Together, these approaches allow the inference of ferroptosis susceptibility within tissue contexts.

In our study, across BC, iron staining did not resolve into a single, reproducible "iron-rich" pattern that could be generalised to all tumours. However, staining intensity ranged from focal strong positivity to weak or absent signal, even within the same tumour. This heterogeneity likely reflects underlying metabolic and microenvironmental differences such as variable oxidative stress, iron turnover, and local inflammatory activity that shape iron handling across intratumoural niches. Iron-positive foci may represent tumour subdomains with increased metabolic activity or oxidative pressure, whereas iron-poor regions may maintain tighter control of iron homeostasis, potentially conferring protection against ferroptotic stress (Torti & Torti, 2013). Our observations of iron deposition in peritumoural regions raise the possibility that the tumour microenvironment actively participates in local iron remodeling. Stromal elements, including tumour-associated macrophages and fibroblasts, are known regulators of iron trafficking and may create microenvironmental iron gradients that influence tumour behaviour (Thielmann et al., 2019). These iron-rich peripheral niches could modulate redox balance and lipid peroxidation potential, thereby shaping regional ferroptosis susceptibility (Marques et al., 2016). While the observed patterns of intratumoral and peritumoral iron deposition may suggest an increased

susceptibility to ferroptosis, they should not be interpreted as direct evidence of ferroptotic cell death. Further studies integrating iron mapping with functional and molecular ferroptosis assays, including assessment of ferroptosis-specific markers, are required to establish a causal link between iron accumulation and ferroptosis activation in BC tissue.

Overall, our findings indicate that iron dysregulation in breast cancer manifests as a spatially heterogeneous distribution of iron rather than as a uniform iron overload. These patterns likely correspond to metabolic and microenvironmental differences that modulate susceptibility to ferroptosis. Understanding how intratumoural and peritumoural iron dynamics contribute to ferroptotic regulation may provide new insights into therapeutic strategies targeting iron metabolism in BC.

Limitations of the Study

This study has several limitations that should be acknowledged. First, the sample size was relatively small (n=20) , limiting the statistical power of the analysis and the generalisability of the findings to the broader breast cancer population. As a result, subgroup analyses according to molecular subtype, tumour grade, or clinical stage could not be performed, nor could potential associations between iron deposition patterns and established clinicopathological parameters be explored. Therefore, the present work should be considered an exploratory, hypothesis-generating study rather than a definitive quantitative assessment of iron metabolism in breast cancer. Although digital pathology and algorithm-based image analysis were employed, the study primarily provides a descriptive and spatial characterisation of iron deposition. Quantitative metrics such as the percentage of iron-positive area, optical density measurements, and formal statistical comparisons between intratumoural and peritumoural regions were limited. Future studies incorporating larger cohorts and robust quantitative and statistical analyses will be required to validate these observations. Second, the analysis of iron deposition was based on Prussian blue staining, which detects ferric iron (Fe3+) but does not directly detect the labile ferrous iron (Fe), the species that drives ferroptosis. Therefore, the staining provides an indirect, rather than a definitive, assessment of ferroptotic susceptibility.

CONCLUSION

In this study, we demonstrated that iron distribution in BC tissues is spatially heterogeneous, with distinct regions exhibiting variable levels. This intratumoural variability suggests that iron handling differs across tumour compartments, potentially reflecting metabolic diversity and differential vulnerability to ferroptosis. Overall, these observations support the growing concept that ferroptosis susceptibility is influenced by BC heterogeneity , which may have implications for future therapeutic targeting.

Ethics Committee Approval

This study was conducted using archival human breast cancer tissue samples obtained from the Nottingham Primary Breast Cancer series. Ethical approval for the use of these samples was granted by the Yorkshire & The Humber - Leeds East Research Ethics Committee under the study title “Refining the prognosis of breast cancer and breast cancer precursor lesions for personalised therapy” (REC reference: 19/YH/0293; IRAS project ID: 266925). In addition, the Breast Pathology Database received ethical approval under REC reference 19/EM/0162 (IRAS project ID: 256309).

Financial Disclosure

B.E. was supported by the Republic of Türkiye Ministry of National Education.

Acknowledgements

We thank the Nottingham Health Science Biobank and Breast Cancer Now Tissue Bank for the provision of tissue samples.

REFERENCES

Carroll, J. C., Cremin, C., Allanson, J., Blaine, S. M., Dorman, H., Gibbons, C. A., Grimshaw, J., Honeywell, C., Meschino, W. S., Permaul, J., & Wilson, B. J. (2008). Hereditary breast and ovarian cancers. *Canadian Family Physician Medecin de Famille Canadien*, 54(12),1691–1692.

Chen, Z., Lin, H., Wang, X., Li, G., Liu, N., Zhang, M., & Shen, Y. (2024). The application of approaches in detecting ferroptosis. *Heliyon*, 10(1),e23507. https://doi.org/10.1016/j.heliyon.2023.e23507

Dai, Z., Liu, J., Zeng, L., Shi, K., Peng, X., Jin, Z., Zheng, R., & Zeng, C. (2025). Targeting ferroptosis in cancer therapy: Mechanisms, strategies, and clinical applications. *Cell Investigation*, 1(4),100049. https://doi.org/10.1016/j.clnves.2025.100049

Ding, X., Cui, L., Mi, Y., Hu, J., Cai, Z., Tang, Q., Yang, L., Yang, Z., Wang, Q., Li, H., Hou, B., Liu, Q., Zou, Z., & Chen, Y. (2025). Ferroptosis in cancer: revealing the multifaceted functions of mitochondria. *Cellular and Molecular Life Sciences*, 82(1).https://doi.org/10.1007/s00018-025-05812-8

Feng, S., Tang, D., Wang, Y., Li, X., Bao, H., Tang, C., Dong, X., Li, X., Yang, Q., Yan, Y., Yin, Z., Shang, T., Zheng, K., Huang, X., Wei, Z., Wang, K., & Qi, S. (2023). The mechanism of ferroptosis and its related diseases. *Molecular Biomedicine*, 4(1).https://doi.org/10.1186/s43556-023-00142-2

Ge, A., He, Q., Zhao, D., Li, Y., Chen, J., Deng, Y., Xiang, W., Fan, H., Wu, S., Li, Y., Liu, L., & Wang, Y. (2024). Mechanism of ferroptosis in breast cancer and research progress of natural compounds regulating ferroptosis. *Journal of Cellular and Molecular Medicine,* 28(1). https://doi.org/10.1111/jcmm.18044

Liu, S., Zhang, X., Wang, W., Li, X., Sun, X., Zhao, Y., Wang, Q., Li, Y., Hu, F., & Ren, H.(2024).Metabolic reprogramming and therapeutic resistance in primary and metastatic breast cancer. *Molecular Cancer*, 23(1). https://doi.org/10.1186/s12943-024-02165-x

Liu, W., Jiang, C., Ma, Y., Wang, W., Peng, J., Ma, W., Xu, S., & Wu, D. (2024). The impact of ferroptosis and ferroptosis-related non-coding RNAs on breast cancer progression. *Frontiers in Cell and Developmental Biology*, 12(12),1–20. https://doi.org/10.3389/fcell.2024.1506492

Liu, Y., Hu, Y., Jiang, Y., Bu, J., & Gu, X. (2022). Targeting ferroptosis, the achilles' heel of breast cancer: A review. *Frontiers in Pharmacology*, 13, 1036140. https://doi.org/10.3389/fphar.2022.1036140

Łukasiewicz, S., Czeczelewski, M., Forma, A., Baj, J., Sitarz, R., & Stanisławek, A. (2021). Breast Cancer-Epidemiology, Risk Factors, Classification, Prognostic Markers, and Current Treatment Strategies-An Updated Review. *Cancers,* 13(17). https://doi.org/10.3390/cancers13174287

Mao, Y., Xia, Z., Xia, W., & Jiang, P. (2024). Metabolic reprogramming, sensing, and cancer therapy. *Cell Reports*, 43(12),115064. https://doi.org/10.1016/j.celrep.2024.115064

Marques, O., Porto, G., Rêma, A., Faria, F., Cruz Paula, A., Gomez-Lazaro, M., Silva, P., Martins da Silva, B., & Lopes, C. (2016). Local iron homeostasis in the breast ductal carcinoma microenvironment. *BMC Cancer*, 16(1),1–14. https://doi.org/10.1186/s12885-016-2228-y

Mellor, H. R., & Callaghan, R. (2008). Resistance to chemotherapy in cancer: A complex and integrated cellular response. *Pharmacology,* 81(4), 275–300. https://doi.org/10.1159/000115967

Sonoda, A., Nihei, M., Shinkawa, N., Kakizaki, E., & Yukawa, N.(2025).Perls' Prussian blue staining and chemistry of Prussian blue and Turnbull blue. Forensic Science International: Synergy, 11(December 2024),100627. https://doi.org/10.1016/j.fsisyn.2025.100627

Thi Nghiem, T. H., Kusuma, F., Park, J., Joe, Y., Chung, H. T., & Han, J. (2025). Brief guide to detecting ferroptosis. *Molecules and Cells,* 48(11), 100276. https://doi.org/10.1016/j.mocell.2025.100276

Thielmann, C. M., Costa da Silva, M., Muley, T., Meister, M., Herpel, E., & Muckenthaler, M. U. (2019). Iron accumulation in tumor-associated macrophages marks an improved overall survival in patients with lung adenocarcinoma. *Scientific Reports*, 9(1),1–9. https://doi.org/10.1038/s41598-019-47833-x

Torti, S. V., & Torti, F. M. (2013). Iron and cancer: More ore to be mined. *Nature Reviews Cancer*, 13(5),342–355. https://doi.org/10.1038/nrc3495

Vidal, M., Paré, L., & Prat, A.(2016).Molecular classification of breast cancer. Management of Breast Diseases: Second

Edition, 203–219. https://doi.org/10.1007/978-3-319-46356-8_12

World Health Organization(WHO).(n.d.).World Health Organization(WHO).(2022).Breast cancer: Statistics and facts. Retrieved from https://www.who.int.

Yan, H. fa, Zou, T., Tuo, Q. zhang, Xu, S., Li, H., Belaidi, A. A., & Lei, P. (2021). Ferroptosis: mechanisms and links with diseases. *Signal Transduction and Targeted Therapy*, 6(1).https://doi.org/10.1038/s41392-020-00428-9

Zhang, K., Ping, L., Du, T., Liang, G., Huang, Y., Li, Z., Deng, R., & Tang, J.(2021).A Ferroptosis-Related lncRNAs Signature Predicts Prognosis and Immune Microenvironment for Breast Cancer. Frontiers in Molecular Biosciences, 8. https://doi.org/10.3389/fmolb.2021.678877

Zhang, W., Liu, Y., Liao, Y., Zhu, C., & Zou, Z.(2024).GPX4, ferroptosis, and diseases. Biomedicine and Pharmacotherapy, 174, 116512. https://doi.org/10.1016/j.biopha.2024.116512