AHEAD OF PRINT

Crocin attenuates oxidative and inflammatory stress-related periodontitis in cardiac tissues in rats

Gulhan Kocaman[1,A,E,F], Eyup Altinoz[2,B–D], Mehmet Erman Erdemli[3,B,C], Mehmet Gul[4,C], Zeynep Erdemli[3,C], Emrah Zayman[4,C], Harika Gozde Gozukara Bag[5,C], Tugba Aydın[6,E]

[1] Department of Periodontology, Faculty of Dentistry, Karabuk University, Turkey
[2] Department of Medical Biochemistry, Faculty of Medicine, Karabuk University, Turkey
[3] Department of Medical Biochemistry, Faculty of Medicine, Inonu University, Malatya, Turkey
[4] Department of Histology and Embryology, Faculty of Medicine, Inonu University, Malatya, Turkey
[5] Department of Biostatistics, Faculty of Medicine, Inonu University, Malatya, Turkey
[6] Department of Periodontology, Faculty of Dentistry, Ataturk University, Erzurum, Turkey

A – research concept and design; B – collection and/or assembly of data; C – data analysis and interpretation; D – writing the article; E – critical revision of the article; F – final approval of the article

Advances in Clinical and Experimental Medicine, ISSN 1899–5276 (print), ISSN 2451–2680 (online) *Adv Clin Exp Med*. 2021;30(5)

Address for correspondence
Gulhan Kocaman
E-mail: dentist25@hotmail.com

Funding sources
This work was supported by a research fund from Karabuk University, Turkey (grant No. KBU-BAP-17-KP-360).

Conflict of interest
None declared

Received on January 3, 2021
Reviewed on February 22, 2021
Accepted on February 28, 2021

Published online on May 11, 2021

Abstract

Background. Periodontitis, a chronic inflammatory disease affecting the supporting tissues around the teeth, causes significant inflammatory and oxidative changes in cardiac tissue. Crocin is the active constituent of *Crocus sativus* (saffron) which has antioxidant properties and is protective against cardiovascular disturbances.

Objectives. The present study aimed to investigate the protective effects of crocin on periodontitis-induced oxidative/inflammatory cardiac degeneration in rats in vivo.

Materials and methods. Thirty female Sprague Dawley rats were randomly divided into 3 groups: control group, periodontitis group (PD) and periodonditis plus crocin group (PD+Cr). Experimental periodontitis was induced by placing silk ligatures on the maxillary second molar teeth for 30 days. Afterward, crocin (100 mg/kg body weight/day) was administered to the PD+Cr group and saline was administered to the PD group and the control group for 15 days. The subjects were sacrificed on the 45th day.

Results. Histological and biochemical analyses demonstrated that inducing periodontitis caused obvious damage to cardiac tissues which was significantly ameliorated by crocin ($p < 0.05$). Significant improvements in bone resorption parameters (cross-linked C-telopeptide of type I collagen and bone alkaline phosphatase) were also observed in the PD+Cr group ($p < 0.05$). In addition, crocin caused significant reductions of malondialdehyde levels and total oxidant score while antioxidant levels (glutathione, superoxide dismutase, total antioxidant score, and catalase) were significantly higher in PD+Cr group ($p < 0.05$).

Conclusions. This study reveals that periodontitis may cause oxidative damage in cardiac tissue and crocin improves periodontitis-induced degenerative changes in heart tissue, which is associated with its antioxidant properties.

Key words: periodontitis, inflammation, antioxidants, crocin, heart

Cite as
Kocaman G, Altinoz E, Erdemli ME, et al. Crocin attenuates oxidative and inflammatory stress-related periodontitis in cardiac tissues in rats [published online as ahead of print on May 11, 2021]. *Adv Clin Exp Med*. 2021;30(5). doi:10.17219/acem/133753

DOI
10.17219/acem/133753

Copyright
© 2021 by Wroclaw Medical University
This is an article distributed under the terms of the Creative Commons Attribution 3.0 Unported (CC BY 3.0) (https://creativecommons.org/licenses/by/3.0/)

provisional PDF only

Background

Oxidative stress results from changes in the balance between reactive oxygen species (ROS) and antioxidant capacity.[1] The ROS overproduction causes irreversible damage to biomolecules (such as membrane lipids, proteins and DNA) that are crucial to tissue and cellular function.[2] One of the most important health conditions affected by oxidative stress is cardiac failure. While myocardial antioxidants such as superoxide dismutase (SOD), catalase (CAT), glutathione peroxidase (GSH-Px), and vitamin E decrease in the heart tissue of patients with heart failure, free oxygen radicals and oxidative stress increase.[3] The ROS disrupt the contractile functions of the myocardium by directly affecting the proteins responsible for contraction–excitation coupling. They activate kinase signaling in hypertrophy and disrupt extracellular matrix remodeling by initiating matrix metalloproteases (MMPs).[4] Periodontal disease, associated with chronic inflammation, is characterized by high amounts of ROS, which cause increased oxidative damage in gingival tissue, periodontal ligaments and alveolar bone.[5]

The significant increase in cardiac oxidative stress caused by periodontitis is reportedly attributable to an excessive increase in ROS production rather than decreased antioxidant capacity. Moreover, cardiac oxidative stress associated with periodontitis may contribute to the pathological process leading to heart failure.[6] It has often been suggested that antioxidants limit oxidative damage in humans, thereby reducing the risk of some chronic health conditions, such as cardiovascular disease (CVD).[7]

Since ancient times, saffron (*Crocus sativus L.*) has been widely used as a spice, food colorant and alternative medicine to treat some diseases. In addition to the 3 main ingredients, crocin, crocetin and safranal, dried saffron contains almost 150 components including carotenoids, sugars, proteins, anthocyanins, vitamins, and minerals. Besides its strong antioxidant properties, saffron is used as a natural/traditional medicine for disease treatment due to its anti-inflammatory, anticarcinogenic and antioxidant effects.[8] Carotenoids from saffron are free radical scavengers, especially against superoxide anions,[9] and could thus prevent oxidative damage. A considerable amount of evidence shows that crocin can effectively improve CVDs such as atherosclerosis, hyperlipidemia, hypertension, and myocardial injury.[10]

Experimental studies show that periodontitis, a chronic, systemic disease characterized by low-grade inflammation and oxidative stress, causes significant inflammatory and oxidative changes in cardiac tissue.[6,11] Although the cardioprotective effect of crocin is well known, information about its protective effects on periodontitis-related cardiac alterations is lacking.

Objectives

This study aimed to investigate the potential effects of periodontitis on the oxidative stress levels in cardiac tissue and the therapeutic activity of systemic crocin administration in such cases.

Materials and methods

Animals and experimental design

Thirty adult female Sprague Dawley rats weighing between 225 g and 250 g were used in this study. The rats were obtained from the Inonu University, Experimental Animals Production and Research Centre (INUTF-DEHUM), Malatya, Turkey. This study was authorized by the Inonu University Experimental Animals Ethics Committee. All experimental procedures were carried out at INUTF-DEHUM. The rats were housed in a room at 21°C, with 55–60% humidity and a 12 h light (08:00–20:00)–12 h dark (20:00–08:00) cycle. The rats consumed a soft diet ad libitum throughout the study period. Cage maintenance and drinking water changes were performed daily.

First, the experimental animals were deeply anesthetized by xylazine and ketamine to induce a periodontitis model. The maxillary right second molar teeth were enclosed with silk suture 5-0 and tied to the vestibule teeth. This ligature encompassing the molar teeth promoted bacterial accumulation, which led to inflammation and bone loss. After 30 days, the ligatures were discarded to permit a decrease in inflammation and allow healing. All rats were inspected for the development of periodontitis.[12]

The rats were randomly divided into 3 groups with 10 rats in each group. The control group received normal saline orally throughout the study. The periodontal disease (PD) group received normal saline orally following removal of the ligature. The periodontal disease plus crocin (PD+Cr) group received 100 mg/kg/day of crocin (Sigma-Aldrich, St. Louis, USA) orally following removal of the ligature.[13] The crocin was dissolved in normal saline and administered over 15 days to the rats in the PD+Cr group. Both the control and PD group received 1 mL of normal saline for 15 days. All animals were anesthetized with xylazine and ketamine, and heart tissue and 5 mL of blood were collected from their abdominal veins.

Samples

The heart tissue samples collected from all of the animals were used for biochemical and histological evaluations. The samples were washed with saline and divided into halves. The fragments of the 1st half were fixed in 10% formaldehyde, and those of the 2nd half were stored

provisional PDF only

at −80°C until biochemical analyses were performed. Serum samples were obtained from the blood samples via centrifuging at 600 × g for 20 min. Moreover, the right maxillary alveolar bones of the rats belonging to all groups were collected for histopathological examination to prove experimental periodontitis.

Biochemistry

Stored tissue samples were thawed and weighed just before the analyses. The tissues were mixed with phosphate buffer and homogenized for 1–2 min on ice at 12,000 rpm (IKA Ultra Turrax T-25 basic; IKA Labotechnik, Staufen, Germany) to procure 10% homogenates. Malondialdehyde (MDA) levels were measured in the homogenate, and the remaining was centrifuged at 600 × g for 30 min at 4°C to obtain a supernatant. All other biochemical analyses were conducted on the supernatant. Cross-linked C-telopeptide of type I collagen (CTx1), bone alkaline phosphatase (b-ALP), lactate dehydrogenase (LDH), and creatine kinase myocardial band (CK-MB) analyses were performed on the serum samples.

Measurement of tissue MDA levels

The MDA analyses were performed as described previously.[14] The tissue homogenate was mixed with 1% H_3PO_4 and 0.6% thiobarbituric acid, and the mixture was incubated in a boiling water bath for 45 min. Then, the mixture was extracted with n-butanol. The pink product was measured at 535 nm with a spectrophotometer (T80 UV/vis spectrometer; PG Instruments Ltd., Leicestershire, UK) and used to calculate the MDA level. The n-butanol was used as the blind, and tetramethoxypropane was used as the standard. The findings were noted as nM/g wet tissue (gwt).

Measurement of tissue glutathione levels

The glutathione (GSH) levels were measured as described previously.[15] 5,5'-dithiobis 2-nitrobenzoic acid (DTNB) was added to the supernatants, and a yellow-green color was observed. The colored product was measured at 410 nm and used to calculate the GSH level. Distilled water was used as the blank. The results were noted as nM/gwt.

Measurement of tissue SOD activity

The SOD activities were determined as described previously.[16] The supernatants were mixed with xanthine oxidase and an assay reagent mixture to expose the superoxide radicals to xanthine-xanthine oxidase, which generates a blue-colored formazan. Next, the SOD activities were measured at 560 nm and recorded as U/g protein.

Measurement of tissue CAT activity

The CAT activities were determined as previously described.[17] The supernatants were mixed with phosphate buffer (pH: 7.5 mM) containing H_2O_2. The CAT in the supernatant breaks down H_2O_2 into H_2O and O_2, which reduces the absorbance at 240 nm. The reduction in absorbance was observed for 1 min to calculate the enzyme activity. The CAT activities were noted as K/g protein.

Measurement of tissue total oxidant status

The total oxidant status (TOS) was ascertained using Erel's method.[18] A commercially-available TOS kit (Rel Assay Diagnostics, Gaziantep, Turkey) was utilized according to the manufacturer's instructions. An enzyme-linked immunosorbent assay (ELISA) reader was used to measure TOS at 25°C and 530 nm. The data were presented as μM H_2O_2 equiv/L.

Measurement of tissue total antioxidant status

The total antioxidant status (TAS) was ascertained using Erel's method.[19] A commercially-available TAS kit (Rel Assay Diagnostics) was utilized according to the manufacturer's instructions. Following preparation of the samples, absorptions were measured at 660 nm. The data were presented as mM Trolox equiv/L.

Measurement of serum CTx1 and b-ALP levels

Serum CTx1 and b-ALP concentrations were measured using a commercially-available, rat-specific CTx1 ELISA kit (Elabscience, Houston, USA) and a rat-specific b-ALP ELISA kit (Elabscience) according to the manufacturer's instructions at 37°C and 450 nm. The results were noted as ng/mL.

Measurement of serum CK-MB and LDH levels

Serum LDH and CK-MB were measured via commercially-available Architect c1600 automatic analyzer kits (Abbott, Abbott Park, USA). The results were noted as U/L.

Histopathology

For 48 h, the heart tissue samples were fixed in 10% neutral-buffered formaldehyde. The maxillary bone was fixed and decalcified in a 50% RDO (R) solution (Apex Engineering Products Corporation, Aurora, USA) for 12 h. Following dehydration in ethanol series (50–99%) and clearing

provisional PDF only

in xylene series, both tissues were embedded in paraffin wax. Five sections of 6 µm thickness each were taken from each paraffin block at 100 µm intervals. The sections were placed on slides and stained with hematoxylin and eosin (H&E). All of the sections were examined with ×20, ×40 and ×100 magnification objective lenses of light 203 microscopes (Nikon Eclipse Ni-U; Nikon Corp., Tokyo, Japan) with a camera attachment (Nikon DS-Fi2; Nikon Corp.), and 204 microscopic images were evaluated using an image analysis system (Nikon NIS-Elements Documentation 205 5.02; Nikon Corp.).

Histological alterations of the cardiomyocytes, in terms of order and integrity, vacuolization, hyalinization, and nuclear pyknosis, were scored on a semi-quantitative scale of 0–3 (normal – 0, minimal changes – 1, moderate changes – 2, and severe changes – 3). The prevalence of each degree of these findings was scored as "1" (<10%), "2" (11%–20%), "3" (21%–40%), or "4" (>40%). Total histologic damage scores were obtained by multiplying the scores of the histological alterations with the prevalence degree scores. The scoring system described by Ziebolz et al.[20] was modified and used. The maximum total score was 48.

Statistical analyses

Statistical analyses were performed using IBM SPSS Statistics for Windows v. 22.0 (IBM Corp., Armonk, USA). The Shapiro–Wilk test was used to assess data normality. The findings were summarized as the mean and standard deviation (SD). The homogeneity of the variances was analyzed using the Levene's test. Groups with homogeneous variances were evaluated with one-way analysis of variance (ANOVA) and the Tukey's honestly significant difference post hoc method. The Welch test and the Tamhane T2 pairwise comparison method were used for groups with heterogeneous variances. The histological scorings were presented as median, minimum and maximum values. The groups were compared with the Kruskal–Wallis test and the Conover pairwise comparison method. In all analyses, p-value <0.05 was considered significant.

Results

Biochemistry

The oxidant/antioxidant ratios within the heart tissues are listed in Table 1. The MDA level in rats with induced periodontitis showed an insignificant elevation compared to the control group. However, following the crocin treatment, the MDA levels decreased notably and were close to those in the control group ($p < 0.05$). Moreover, the TOS levels in the PD group were significantly elevated compared to those in the control group and the PD+Cr group ($p < 0.05$). On the other hand, the PD+Cr group showed significantly lower TOS levels compared to the PD group ($p < 0.05$). In contrast, non-enzymatic antioxidants, GSH levels, enzymatic antioxidants, and SOD and CAT enzyme activities were significantly reduced in the heart tissue of the rats with induced periodontitis compared to the tissues of both the control group and PD+Cr group ($p < 0.05$). Furthermore, the crocin treatment significantly elevated them compared to the corresponding value for the PD group ($p < 0.05$). While the TAS of the heart tissue was significantly decreased in both the PD and PD+Cr groups compared to the control groups ($p < 0.05$), it was significantly elevated in the PD+Cr compared to the PD group ($p < 0.05$).

The results of the biochemical analyses showing serum bone destruction and heart tissue injury indicators appear in Table 2. While periodontitis induction significantly elevated serum CTx1 levels in the control group and the PD+Cr group ($p < 0.05$), the serum b-ALP levels decreased significantly ($p < 0.05$). Following crocin treatment, both the CTx1 and b-ALP levels were significantly ameliorated compared to those of the PD group ($p < 0.05$). Moreover, while significant elevations were observed in the LDH and CK-MB levels of the PD group ($p < 0.05$) following the crocin treatment, they decreased slightly compared to the PD group.

Histopathology

The heart tissue sections of the control group were observed to have a normal histological structure. No

Table 1. Oxidant/antioxidant parameters of heart tissue

Group	MDA [nmol/gwt]	GSH [nmol/gwt]	SOD [U/g protein]	CAT [K/g protein]	TAS [mmol/L]	TOS [µmol/L]
Control	441.38 ±39.67^{a,b}	1241.13 ±32.09^{a}	71.01 ±5.00^{a}	11.33 ±2.65^{a}	2.21 ±0.08^{a}	2.42 ±0.24^{a}
PD	669.50 ±207.52^{a}	1170.13 ±25.23^{b}	24.92 ±3.86^{b}	2.64 ±1.24^{b}	1.24 ±0.03^{b}	14.7 ±1.91^{b}
PD+Cr	422.00 ±80.54^{b}	1247.75 ±49.85^{a}	60.20 ±5.59^{c}	8.28 ±2.94^{c}	1.55 ±0.10^{c}	8.06 ±0.86^{c}
p-value	0.032	0.001	<0.001	<0.001	<0.001	<0.001

Data are expressed as means ± standard deviation (SD) (n = 10). MDA – malondialdehyde; GSH – reduced glutathione; SOD – superoxide dismutase; CAT – catalase; TAS – total antioxidant status; TOS – total oxidant status; gwt – gram wet tissue. Groups: control group received normal saline solution, periodontitis (PD) group received normal saline solution and periodonditis plus crocin (PD+Cr) group received crocin. Statistically significant differences between groups are denoted with different superscript letters ($p < 0.05$).

provisional PDF only

Table 2. Biochemical analysis of serum markers related to bone resolution and cardiac injury

Groups	CTx1 [ng/mL]	b-ALP [ng/mL]	LDH [U/L]	CK-MB [U/L]
C	4.19 ±0.24[a]	1.72 ±0.25[a]	176.38 ±42.66[a]	191.84 ±40.69[a]
PD	8.53 ±1.08[b]	0.55 ±0.09[b]	345.50 ±154.25[b]	280.63 ±84.46[b]
PD+Cr	5.91 ±0.86[c]	1.04 ±0.20[c]	208.38 ±111.28[a,b]	251.00 ±67.86[a,b]
p-value	<0.001	<0.001	0.041	0.032

Data are expressed as means ± standard deviation (SD) (n = 10). CTx1 – cross-linked C-telopeptide of type I collagen; b-ALP – bone-specific alkaline phosphatase; LDH – lactate dehydrogenase; CK-MB – heart-specific creatine kinase. Groups: control group received normal saline solution, periodontitis (PD) group received normal saline solution and periodontitis plus crocin (PD+Cr) group received crocin. Statistically significant differences between groups are denoted with different superscript letters ($p < 0.05$).

cardiomyocyte damage was detected in the cardiac tissue sections of the control group rats. The cardiomyocytes in the heart tissue sections of these rats showed typical cardiomyocyte order and integrity upon microscopic examination (Fig. 1A–C).

The heart section evaluations of the PD group indicated different cardiomyocyte prevalence and degrees of disorganization and deformity, hyalinization, intracytoplasmic vacuolization, and nuclear pyknosis (Fig. 1D–F). The total histological damage score of this group was determined

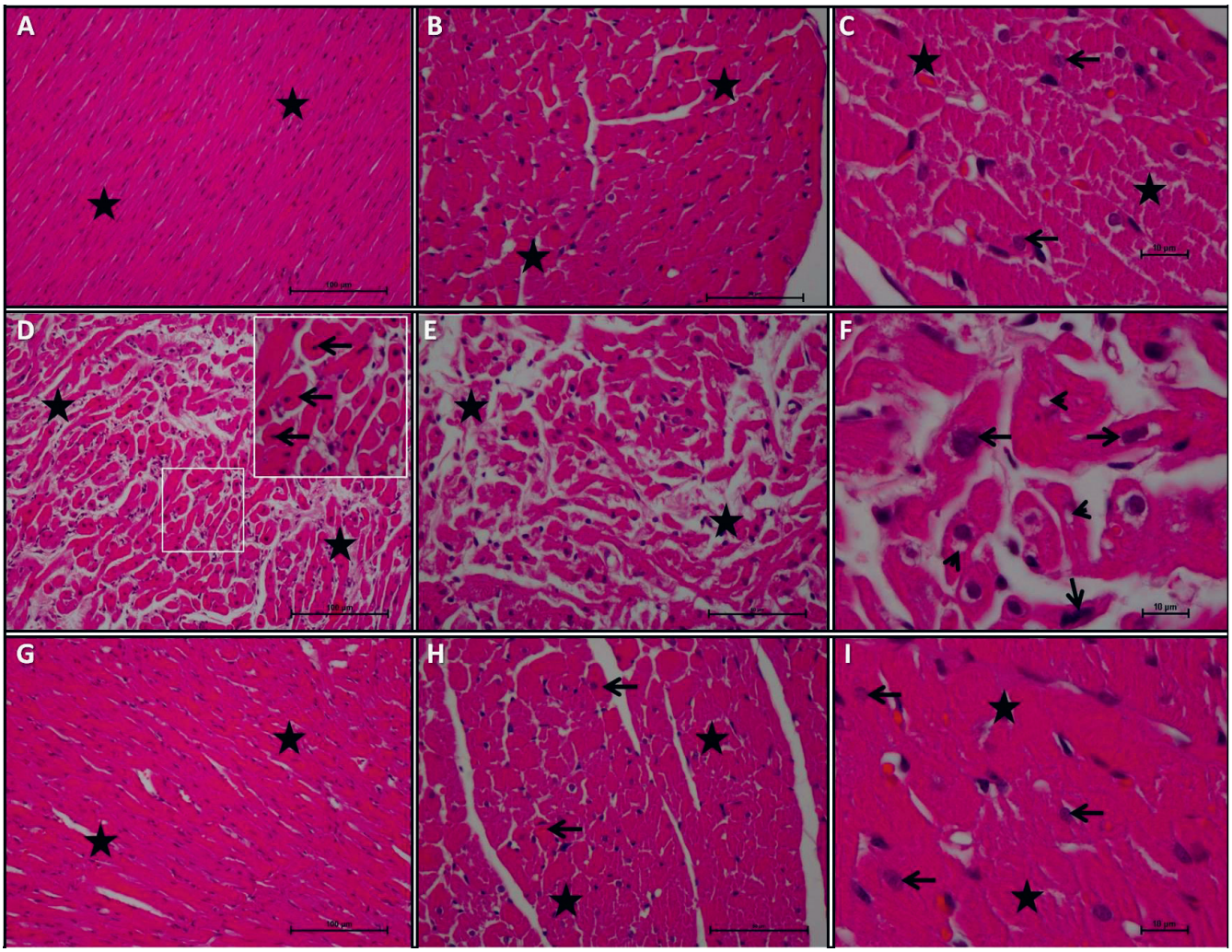

Fig. 1. Cardiac photomicrographs. A–C. Control group – myocardium layer. Cardiomyocytes with normal histological appearance at the transverse section plane (asterisk), cardiomyocyte nuclei (arrow). A. H&E staining, ×20 magnification; B: H&E staining, ×40 magnification; C: H&E staining, ×100 magnification. D–F. PD group – myocardium layer. Shape and organization disorder in cardiomyocytes (asterisk), pyknotic nuclei and hyalinization in cardiomyocytes (arrow), intracytoplasmic vacuoles in cardiomyocytes (arrowhead); D. H&E staining; large figure ×20 magnification, small figure ×40 magnification; E. H&E staining, ×40 magnification; F. H&E staining, ×100 magnification; G–I. PD+Cr group – myocardium layer at longitudinal section plane (asterisk), minimal cytoplasmic hyalinization and pyknotic nuclei in cardiomyocytes (arrow); G. H&E staining, ×20 magnification; H. H&E staining, ×40 magnification; I. H&E staining, ×100 magnification

provisional PDF only

Table 3. Cardiac tissue damage scores

Groups	Cardiomyocytes order and integrity	Intracytoplasmic vacuolization	Hyalinization	Nuclear pyknosis	Total scores
C	0 (0–0) [a]	0 (0–0) [a]	0 (0–0) [a]	0 (0–0) [a]	0 (0–0) [a]
PD	4 (2–6) [b]	4 (1–6) [b]	2 (1–4) [b]	2 (1–4) [b]	12 (7–15) [b]
PD+Cr	1 (0–2) [c]	0 (0–2) [c]	1 (0–2) [c]	1 (0–2) [c]	3 (2–4) [c]
p-value	<0.001	<0.001	0.0016	<0.001	<0.001

Data are expressed as min–max (n = 10). Groups: control group received normal saline solution, periodontitis (PD) group received normal saline solution and periodontitis plus crocin (PD+Cr) group received crocin. Statistically significant differences between groups are denoted with different superscript letters ($p < 0.05$).

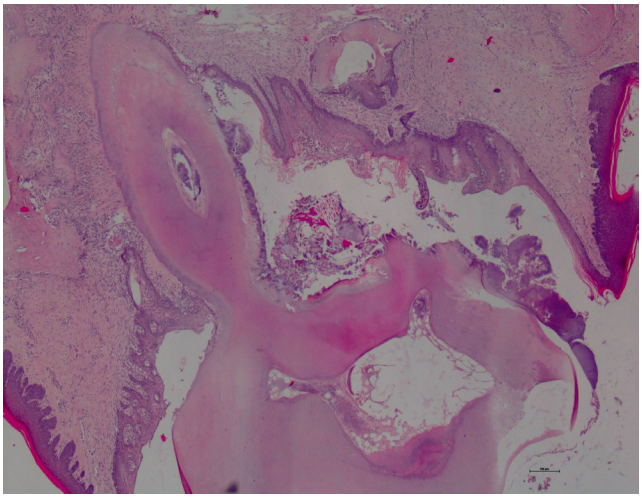

Fig. 2. Gingival photomicrograph

to be 12. The cardiac tissue damage scores are presented in Table 3.

The PD+Cr group showed significant decreases in all damage parameters compared to the PD group (Fig. 1G–I). The total histological damage score of the PD+Cr group was determined to be 3.

Figure 2 presents the histopathology of the gingiva tissue of a rat in the PD group. Inflammatory cell infiltration of the connective tissue epithelium and degeneration of the gingival epithelium were observed. Inflammatory cell infiltration in the fibrous connective tissue and degeneration sites in the periodontal ligament were defined. The cementum and alveolar bone surfaces were irregular due to several Howship's lacunae with differently-sized osteoclastic activity sites towards the periodontal ligament, and the histological images reflected increased bone resorption.

Discussion

The ROS, which play an important role in the pathogenesis of periodontitis, are caused either by the oral bacteria themselves or the stimulated immune response. Furthermore, polymorphonuclear leukocytes, the main protective cells against oral pathogenic bacteria, are responsible for the formation of ROS during phagocytosis.[5] In this study, bone resorption and inflammatory alterations were evaluated via a comparison of the serum CTx1 and b-ALP levels. Arabacı et al.[12] showed that serum b-ALP levels were significantly elevated in their periodontitis-induced group after melatonin treatment. Similarly, our study revealed that b-ALP levels, which reflect bone destruction induced by periodontitis, were significantly elevated following crocin treatment. The CTx1 released during bone resorption is one of the most widely studied and utilized bone resorption markers.[21] Some studies reported that an elevated serum CTx1 level in periodontitis is an indicator of bone destruction, and previous studies showed that serum CTx1 levels are higher in rats with periodontitis.[22,23] In this research, serum CTx1 levels were higher in the PD group compared to the control group and the PD+Cr group, which confirms the findings of previous research and suggests that elevated serum CTx1 levels are related to alveolar bone loss in periodontitis.[23] Moreover, the lower CTx1 level of the PD+Cr group compared to that of the PD group indicates that crocin exhibits its modulating effects on the bone cycle by repressing oxidative stress.

Periodontal disease is initiated by production of inflammatory mediators. These processes lead to loss of periodontal tissue structure and function. Pathogenic bacterial infections play a role in susceptibility to ROS and oxidative stress. Periodontal inflammation is a risk factor for systemic inflammation and eventually CVD. Therefore, 2 common hypotheses are proposed regarding the relationship between periodontitis and CVD: 1) bacteria may affect the vascular system directly[24]; or (2) local inflammation in the periodontal tissues may induce an inflammatory response in distant regions even without the dispersion of the infectious agent.[25] Prior findings support the latter hypothesis, and oxidative stress generated due to periodontitis may initiate the inflammatory damage that occurs in the early stages of atherosclerosis.[26] Furthermore, the systemic inflammation induced by periodontitis may accelerate atherosclerotic vascular damage and plaque rupture. Therefore, periodontitis, rather than a co-existing condition, is likely to cause CVD. Moreover, in this study, periodontal infection/inflammation may have directly or indirectly induced pathological alterations in the heart tissue and thus played a role in cardiac injury.

Neutrophils are responsible for the initiation of inflammation. The oxidative killing mechanisms of neutrophils

provisional PDF only

involve ROS production.[5] Although ROS essentially aim to eliminate bacteria, since they are dispersed to external tissues, they also destroy periodontal tissues. Moreover, they play a role in the pathogeneses of some inflammatory diseases, such as heart and vascular diseases.[27] Lipid peroxidation might play an important role in the onset of CVD, especially in the earliest periods.[28] A study on cardiac failure patients reported decreased serum GSH levels and increased serum MDA levels compared to a control group.[29] Conversely, while lipid peroxidation plays a role in CVD development, antioxidants protect against low-density lipoprotein (LDL) oxidation by clearing ROS.[30] Vitamin C may also contribute to the amelioration of atherosclerosis by reducing lipid peroxidation and elevating antioxidant levels. Moreover, another antioxidant, epigallocatechin gallate, reportedly improved the serum lipid profile and cardiac tissue antioxidant parameters in a rat atherosclerosis model.[31]

The most recent pharmacological studies provide some evidence on the potential of crocin as a therapeutic medicine due to its anti-tumoral, antioxidant and free-radical scavenging activities.[9] Antioxidants play a significant role in protecting against free radical-induced tissue injury by scavenging free radicals. Although the mechanism behind the free-radical scavenging effects of crocin as a water-soluble carotenoid is not clear, it is assumed that the mechanistic pathways may be similar to those of known carotenoids. Therefore, crocin may possibly modulate intracellular oxidative stress by regulating the enzymatic antioxidants of the organism when transported to the plasma. It is also reported to have a dose-dependent cytoprotective effect against the endothelial cell damage induced by H_2O_2.[32]

Some studies show that saffron has beneficial effects on CVD treatment.[10] Furthermore, the cardioprotective effects of saffron and its active constituents have been demonstrated in various models. Wang et al.[33] reported that crocin improves cardiac function after myocardial infarction, which in turn increases angiogenesis and myogenesis in the infarcted myocardium. The results of an in vivo rat study by Dianatet al.[34] provided evidence that application of crocin is protective against cardiac dysfunction by exposure to cigarette smoke. Rahiman et al.[35] showed that crocin reduces ROS and protects against oxidative stress in H_2O_2-treated bovine aortic endothelial cells. Xu et al.[32] reported that crocin treatment inhibits atherosclerosis and regression by preventing cell apoptosis. Moreover, He et al.[36] used an animal atherosclerosis model to show that crocin treatment significantly decreases cholesterol, triglyceride and low-density lipoprotein (LDL) levels and restricts aortic plaque formation by decreasing endothelial cell apoptosis. Recently, crocin was found to have a protective effect on the vascular system against diazinon-related apoptosis via inhibition of caspase-dependent apoptosis in rat aortic tissue.[37] Oxidative stress and excessive free radical generation are the main stimuli that induce apoptosis in some diseases, including CVDs. Feidantsis et al.[38] reported that crocin improved heart function in diabetic rats by enhancing the heat shock response, inhibiting apoptosis and normalizing autophagy in cells of the cardiac myocardium. Razavi et al.[39] showed that crocin decreases the Bax/Bcl-2 ratio, release of cytochrome c and caspase-3 activation, thereby demonstrating protective effects against diazinon-related cardiotoxicity by decreasing lipid peroxidation, histopathological alterations and apoptosis. The results of this study revealed that the elevated MDA and TOS levels in the heart tissue of rats with periodontitis can be lowered with crocin treatment. Moreover, crocin treatment following periodontitis induction ameliorated the decline in antioxidants (GSH, TAS, SOD, and CAT) within the heart tissue. The chemical and biological features of crocin manifest its antioxidant and free radical-scavenging properties.[8]

Limitations

The present study has some limitations. Firstly, the study results are not sufficient to suggest a direct relationship between human periodontitis and the short-term outcomes of an experimental periodontitis model. Secondly, study subjects are restricted to female-only rats; therefore, our results are insufficient to make a conclusion for both sexes. Thus, cardiac damage caused by periodontal inflammation and the damage-limiting effects of crocin should be studied more comprehensively and at the ventricular level in both sexes.

Conclusions

Periodontitis is a chronic systemic inflammatory disease and has the potential to increase the risk of cardiac damage/degeneration by causing a significant increase in oxidative damage markers in cardiac tissue. Crocin is an important adjunctive therapeutic agent to mitigate potential cardiac structural damage induced by periodontitis-related inflammation and oxidative damage.

ORCID iDs

Gulhan Kocaman https://orcid.org/0000-0002-8920-2391
Eyup Altinoz https://orcid.org/0000-0002-3991-9773
Mehmet Erman Erdemli https://orcid.org/0000-0003-4596-7525
Mehmet Gul https://orcid.org/0000-0002-5721-8778
Zeynep Erdemli https://orcid.org/0000-0002-9002-6604
Emrah Zayman https://orcid.org/0000-0002-6578-3371
Harika Gozde Gozukara Bag https://orcid.org/0000-0003-1208-4072
Tugba Aydın https://orcid.org/0000-0002-8497-7753

References

1. Chapple IL, Matthews JB. The role of reactive oxygen and antioxidant species in periodontal tissue destruction. *Periodontol 2000*. 2007;43:160–232. doi:10.1111/j.1600-0757.2006.00178.x
2. Chapple I, Brock G, Milward M, Ling N, Matthews J. Compromised GCF total antioxidant capacity in periodontitis: Cause or effect? *J Clin Periodontol*. 2007;34(2):103–110. doi:10.1111/j.1600-051X.2006.01029.x

provisional PDF only

3. Hill MF, Singal PK. Antioxidant and oxidative stress changes during heart failure subsequent to myocardial infarction in rats. *Am J Pathol*. 1996;148(1):291–300. PMID:8546218
4. Cadenas S. ROS and redox signaling in myocardial ischemia-reperfusion injury and cardioprotection. *Free Radic Biol Med*. 2018;117:76–89. doi:10.1016/j.freeradbiomed.2018.01.024
5. Wang Y, Andrukhov O, Rausch-Fan X. Oxidative stress and antioxidant system in periodontitis. *Front Physiol*. 2017;8:910. doi:10.3389/fphys.2017.00910
6. Köse O, Arabacı T, Gedikli S, et al. Biochemical and histopathologic analysis of the effects of periodontitis on left ventricular heart tissues of rats. *J Periodontal Res*. 2017;52(2):176–185. doi:10.1111/jre.12380
7. Neha K, Haider MR, Pathak A, Yar MS. Medicinal prospects of antioxidants: A review. *Eur J Med Chem*. 2019;178:687–704. doi:10.1016/j.ejmech.2019.06.010
8. Rios J, Recio M, Giner R, Manez S. An update review of saffron and its active constituents. *Phytother Res*. 1996;10(3):189–193. doi:10.1002/(SICI)1099-1573(199605)10:3<189::AID-PTR754>3.0.CO;2-C
9. Erben-Russ M, Michel C, Bors W, Saran M. The reaction of sulfite radical anion with nucleic acid components. *Free Radic Res Commun*. 1987;2(4–6):285–288. doi:10.3109/10715768709065293
10. Alavizadeh SH, Hosseinzadeh H. Bioactivity assessment and toxicity of crocin: A comprehensive review. *Food Chem Toxicol*. 2014;64:65–80. doi:10.1016/j.fct.2013.11.016
11. Köse O, Arabacı T, Yemenoglu H, et al. Influence of experimental periodontitis on cardiac oxidative stress in rats: A biochemical and histomorphometric study. *J Periodontal Res*. 2017;52(3):603–608. doi:10.1111/jre.12428
12. Arabacı T, Kermen E, Özkanlar S, et al. Therapeutic effects of melatonin on alveolar bone resorption after experimental periodontitis in rats: A biochemical and immunohistochemical study. *J Periodontol*. 2015;86(7):874–881. doi:10.1902/jop.2015.140599
13. Sugiura M, Shoyama Y, Saito H, Nishiyama N. Crocin improves the ethanol-induced impairment of learning behaviors of mice in passive avoidance tasks. *Proc Jpn Acad Ser B*. 1995;71(10):319–324. doi:10.2183/pjab.71.319
14. Ohkawa H, Ohishi N, Yagi K. Assay for lipid peroxides in animal tissues by thiobarbituric acid reaction. *Anal Biochem*. 1979;95(2):351–358. doi:10.1016/0003-2697(79)90738-3
15. Ellman GL. Tissue sulfhydryl groups. *Arch Biochem Biophys*. 1959;82(1):70–77. doi:10.1016/0003-9861(59)90090-6
16. Sun Y, Oberley LW, Li Y. A simple method for clinical assay of superoxide dismutase. *Clin Chem*. 1988;34(3):497–500. PMID:3349599
17. Aebi H. Catalase in vitro. *Methods Enzymol*. 1984;105:121–126. doi:10.1016/s0076-6879(84)05016-3
18. Erel O. A new automated colorimetric method for measuring total oxidant status. *Clin Biochem*. 2005;38(12):1103–1111. doi:10.1016/j.clinbiochem.2005.08.008
19. Erel O. A novel automated direct measurement method for total antioxidant capacity using a new generation, more stable ABTS radical cation. *Clin Biochem*. 2004;37(4):277–285. doi:10.1016/j.clinbiochem.2003.11.015
20. Ziebolz D, Rost C, Schmidt J, et al. Periodontal bacterial DNA and their link to human cardiac tissue: Findings of a pilot study. *Thorac Cardiovasc Surg*. 2018;7(1):83–90. doi:10.1055/s-0035-1564689
21. Hlaing TT, Compston JE. Biochemical markers of bone turnover: Uses and limitations. *Ann Clin Biochem*. 2014;51(2):189–202. doi:10.1177/0004563213515190
22. Foureaux RdC, Messora MR, de Oliveira LFF, et al. Effects of probiotic therapy on metabolic and inflammatory parameters of rats with ligature-induced periodontitis associated with restraint stress. *J Periodontol*. 2014;85(7):975–983. doi:10.1902/jop.2013.130356
23. Rodrigues W, Madeira M, Da Silva T, et al. Low dose of propranolol down-modulates bone resorption by inhibiting inflammation and osteoclast differentiation. *Br J Pharmacol*. 2012;165(7):2140–2151. doi:10.1111/j.1476-5381.2011.01686.x
24. Deshpande RG, Khan MB, Genco CA. Invasion of aortic and heart endothelial cells byporphyromonas gingivalis. *Infect Immun*. 1998;66(11):5337–5343. doi:10.1128/IAI.66.11.5337-5343.1998
25. Pouliot M, Clish CB, Petasis NA, Van Dyke TE, Serhan CN. Lipoxin A4 analogues inhibit leukocyte recruitment to *Porphyromonas gingivalis*: A role for cyclooxygenase-2 and lipoxins in periodontal disease. *Biochemistry*. 2000;39(16):4761–4768. doi:10.1021/bi992551b
26. Ekuni D, Tomofuji T, Sanbe T, et al. Vitamin C intake attenuates the degree of experimental atherosclerosis induced by periodontitis in the rat by decreasing oxidative stress. *Arch Oral Biol*. 2009;54(5):495–502. doi:10.1016/j.archoralbio.2009.02.006
27. Li H, Horke S, Förstermann U. Oxidative stress in vascular disease and its pharmacological prevention. *Trends Pharmacol Sci*. 2013;34(6):313–319. doi:10.1016/j.tips.2013.03.007
28. Steinberg D, Parthasarathy S, Carew TE, Khoo JC, Witztum JL. Beyond cholesterol: Modifications of low-density lipoprotein that increase its atherogenicity *N Engl J Med*. 1989;320(14):915–924. doi:10.1056/NEJM198904063201407
29. Tamer L, Sucu N, Polat G, et al. Decreased serum total antioxidant status and erythrocyte-reduced glutathione levels are associated with increased serum malondialdehyde in atherosclerotic patients. *Arch Med Res*. 2002;33(3):257–260. doi:10.1016/s0188-4409(01)00381-2
30. Jialal I, Vega GL, Grundy SM. Physiologic levels of ascorbate inhibit the oxidative modification of low density lipoprotein. *Atherosclerosis*. 1990;82(3):185–191. doi:10.1016/0021-9150(90)90039-I
31. Ramesh E, Elanchezhian R, Sakthivel M, et al. Epigallocatechin gallate improves serum lipid profile and erythrocyte and cardiac tissue antioxidant parameters in Wistar rats fed an atherogenic diet. *Fundam Clin Pharmacol*. 2008;22(3):275–284. doi:10.1111/j.1472-8206.2008.00585.x
32. Xu GL, Qian ZY, Yu SQ, Gong ZN, Shen XC. Evidence of crocin against endothelial injury induced by hydrogen peroxide in vitro. *J Asian Nat Prod Res*. 2006;8(1–2):79–85. doi:10.1080/10286020500044732
33. Wang Y, Wang Q, Yu W, Du H. Crocin attenuates oxidative stress and myocardial infarction injury in rats. *Int Heart J*. 2018;59(2):387–393. doi:10.1536/ihj.17-114
34. Dianat M, Radan M, Badavi M, Mard SA, Bayati V, Ahmadizadeh M. Crocin attenuates cigarette smoke-induced lung injury and cardiac dysfunction by anti-oxidative effects: The role of Nrf2 antioxidant system in preventing oxidative stress. *Respir Res*. 2018:19(1):58. doi:10.1186/s12931-018-0766-3
35. Rahiman N, Akaberi M, Sahebkar A, Emami SA, Tayarani-Najaran Z. Protective effects of saffron and its active components against oxidative stress and apoptosis in endothelial cells. *Microvasc Res*. 2018;118:82–89. doi:10.1016/j.mvr.2018.03.003
36. He SY, Qian ZY, Tang FT, Wen N, Xu GL, Sheng L. Effect of crocin on experimental atherosclerosis in quails and its mechanisms. *Life Sci*. 2005;77(8):907–921. doi:10.1016/j.lfs.2005.02.006
37. Razavi BM, Hosseinzadeh H, Abnous K, Khoei A, Imenshahidi M. Protective effect of crocin against apoptosis induced by subchronic exposure of the rat vascular system to diazinon. *Toxicol Ind Health*. 2016;32(7):1237–1245. doi:10.1177/074823371455494
38. Feidantsis K, Mellidis K, Galatou E, Sinakos Z, Lazou A. Treatment with crocin improves cardiac dysfunction by normalizing autophagy and inhibiting apoptosis in STZ-induced diabetic cardiomyopathy. *Nutr Metab Cardiovasc Dis*. 2018;28(9):952–961. doi:10.1016/j.numecd.2018.06.005
39. Razavi BM, Hosseinzadeh H, Movassaghi AR, Imenshahidi M, Abnous K. Protective effect of crocin on diazinon induced cardiotoxicity in rats in subchronic exposure. *Chem Biol Interact*. 2013;203(3):547–555. doi:10.1016/j.cbi.2013.03.010

provisional PDF only