Arab Journal of Gastroenterology 24 (2023) 129–135

Contents lists available at ScienceDirect

Arab Journal of Gastroenterology

journal homepage: www.journals.elsevier.com/arab-journal-of-gastroenterology

Original article

Histopathological and ultra-structural investigation of the damaging effects of hypoinsulinemia, hyper glycaemia and oxidative stress caused by parenteral nutrition combined with fasting on the small intestine of rabbits

Semra Gürünlüoğlu [a], Mehmet Gül [b], Kubilay Gürünlüoğlu [c,*], Alper Kocbiyik [d], Semir Gül [b], Harika Gözükara Bağ [e], Muhammed Mehdi Üremiş [f], Mehmet Demircan [c]

[a] Department of Pathology, Inonu University, Faculty of Medicine, Malatya, Turkey
[b] Department of Histology and Embryology, Inonu University, Faculty of Medicine, Malatya, Turkey
[c] Department of Pediatric Surgery, Inonu University, Faculty of Medicine, Malatya, Turkey
[d] Istanbul Bakırköy Dr Sadi Konuk Education and Research Hospital, Pathology Laboratory, Istanbul, Turkey
[e] Department of Biostatistics and Medical Informatics, Inonu University, Faculty of Medicine, Malatya, Turkey
[f] Department of Medical Biochemistry, Inonu University, Faculty of Medicine, Malatya, Turkey

ARTICLE INFO

Keywords:
Parenteral nutrition
Starvation
Small intestine
Histopathology
Oxidative stress

ABSTRACT

Background and study aims: Parenteral nutrition (PN) is a life-saving practice when the use of the gastrointestinal tract is not appropriate. Despite its great benefits, however, PN may cause several complications. In this study, we conducted histopathological and ultra-structural examinations of the effect of PN combined with starvation on the small intestines of rabbits.

Materials and methods: Rabbits were divided into four groups. A fasting + PN group was left completely unfed and received all its daily required energy by PN through an intravenous central catheter. An oral feeding + PN group received half the necessary daily calories by oral feeding and the other half through PN. A semi-starvation group received only half the necessary daily calories by oral feeding and no PN. The fourth group, serving as a control, was supplied with its entire daily energy requirements through oral feeding. After 10 days, the rabbits were euthanized. Blood and small intestine tissue samples were collected from all groups. Blood samples were biochemically analysed, and tissue samples were examined by light and transmission electron microscopy.

Results: The fasting + PN group exhibited lower insulin levels, higher glucose levels, and increased systemic oxidative stress than the other groups. Ultra-structural and histopathological examinations revealed a significant increase in apoptotic activity in this group's small intestines and a significant decrease in villus length and crypt depth. Severe damage to the intracellular organelles and nuclei of enterocytes was also observed.

Conclusion: PN combined with starvation appears to cause apoptosis in the small intestine due to oxidative stress and hyperglycaemia with hypoinsulinemia, with destructive effects on small intestine tissue. Adding enteral nutrition to PN may reduce these destructive effects.

Introduction

Parenteral nutrition (PN) is a life-saving procedure whereby the body's nutritional, mineral, and liquid-electrolyte needs are met when the use of the gastrointestinal tract is not appropriate [1]. Since the first known attempt to deliver an intravenous nutritional supplement by Sir Cristopher Wren in 1658, parenteral nutrition has developed impressively [2]. In the early 1900s, with the spread of surgical treatments, the importance of preoperative and postoperative nutritional support became obvious [2,3]. In injuries and diseases treated surgically, nutritional requirements increase due to increased catabolism and affect the success of the treatment [3,4]. Although the ideal way to provide nutritional support is via the alimentary tract, in some cases, this route cannot be used for a certain period [4,5]. In these cases, PN

Abbreviations: PN, Parenteral nutrition; TAC, Total antioxidant capacity; TOC, Total oxidant capacity; H&E, Haematoxylin and Eosin; OSI, Oxidative Stability Index.

* Corresponding author at: Inonu University, Faculty of Medicine, Department of Pediatric Surgery, Malatya 44210, Turkey.
E-mail address: kgurunluoglu@hotmail.com (K. Gürünlüoğlu).

https://doi.org/10.1016/j.ajg.2023.02.003
Received 20 January 2021; Accepted 19 February 2023
Available online 6 March 2023
1687-1979/© 2023 Pan-Arab Association of Gastroenterology. Published by Elsevier B.V. All rights reserved.

positively affects the treatment's success [4]. The use of central catheters and concentrated glucose and amino acid solution infusions has been a critical development [2].

Despite its great benefits, however, PN may cause several complications [1,2,6–12]. Many studies have reported complications related to the composition of PN formulas [6–10]. Hepatobiliary, infection, overfeeding, and technical complications have been widely reported [2]. Other complications include liver steatosis, cholestasis, portal inflammation, liver disease, intestinal bacterial colonization, sepsis, heavy metal accumulation in organs, vascular endothelial damage, and cardio toxic effects related to hyperglycaemia complication [1,2,6–12]. In a previous experimental study, we observed destructive cardiac effects due to PN when combined with starvation [11]. This suggests that the toxic effects that are expected of PN can be devastating when it is combined with starvation.

The mechanism that turns the combination of PN with starvation into a destructive force in small intestine tissue has yet to be elucidated. This study aimed to investigate the damaging effect of PN on the small intestines of rabbits histopathologically and ultra-structurally and to examine whether the damage had devastating effects when PN was combined with starvation.

Materials and methods

Groups and parenteral and oral nutrition protocols

This study was approved by the Experimental Animal Ethics Committee of Inonu University, Malatya, Turkey (decision number: 2020/16-13) and was conducted at the university's Experimental Animal Production and Research Centre.

Adult female and male New Zealand rabbits were used in this study. A power analysis showed 90% power with groups consisting of 14 rabbits. Accordingly, four groups consisting of 14 rabbits each were formed. Equal numbers of females and males were randomly assigned to each group using an open-access web-based application. To investigate the effect of PN combined with starvation, two PN groups were formed: a fasting + PN group and an oral feeding + PN group. Both groups received a total of 204 kcal/kg/day [8,11], which meets their daily energy requirements (Table 1). Oral feeding + PN group received half of the total energy through oral feeding + the other half with PN. To investigate the effect of starvation on the small intestine independently of PN application, a semi-starvation group was formed, which was fed the equivalent of half the daily calorie requirements (102 kcal/kg/day). A fourth group, which was fed a diet providing 204 kcal/kg/day, served as a control.

The rabbits were kept in a room in 12/12-h light/dark cycle conditions at an average temperature of 20–23 °C and 40–60 % average relative humidity. Before the experiment, all rabbits were weighed, and their weights were recorded. The experiment lasted 10 days. The rabbits in the fasting + PN group received 230-ml/kg PN every 24 h and were left completely unfed during this time. The rabbits in the oral feeding + PN group received 115-ml/kg PN, amounting to 102 kcal/kg, and rabbit pellet feed providing 102 kcal/kg (18,75% protein, 6.38% cellulose, 2.28 % fat, 6.2% ash, 2.45% minerals, 0.98% lysine, 0.36% methionine 12% starch, 240 kcal/100gr and; TV-01 Rabbit pellet feed, DSA Agrifood Products TS Inc. Kırıkkale, Turkey) every day. The PN formula was composed of trace elements (Addamel N, Fresenius Kabi, Uppsala, Sweden), 10% (w/v) amino acids (Primene, E. Baxter, Istanbul, Turkey), 30% dextrose (Polifleks, Polifarma, Tekirdag, Turkey), and 20% (w/v) lipids (20% Lipofundin MCT/LCT, B. Braun, Melsungen, Germany). The semi-starvation group was fed an amount of rabbit feed (TV-01 Rabbit pellet feed) that provided 102 kcal/kg/day. The control group was fed rabbit feed (TV-01 Rabbit pellet feed) providing 204 kcal/kg/day. All groups were provided with water ad libitum.

In the two PN groups, central catheters were inserted following the cut-down procedure in sterile conditions. During the procedure, 6-mg/kg Xylazine (2% Xylazinbio 50 ml vial, Bioveta PLC. Komenskeho, Czech Republic) and 35-mg/kg ketamine (100 mg/ml Keta-Control 25 ml vial; Arion Pharmaceutical Industry Inc., Tuzla, Istanbul, Turkey) were administered intramuscularly to induce anaesthesia. A polyethylene catheter (20 G cut-down catheter; UPS Medical Instruments Co., Ltd., Ankara, Turkey) was inserted through the right internal jugular vein about 2 cm inside for the cut-down procedure with the rabbits placed in the supine position. The proximal catheter emerged from the nape of the neck through a subcutaneous tunnel and was fixed in place with an absorbable suture. All operations were performed on the same day.

During the experimental period, peripheral blood glucose levels were measured with a glucose meter (Sinocare; Shanghai International Holding Corp., Hamburg, Germany) twice a day. During the study period, all study team members kept watch in the rabbits' room in pairs on three shifts per day to resolve any technical issues during PN administration.

At the end of the experiment, each rabbit's weight was recorded. All

Table 1
Parenteral nutrition solution formula (total liquid volume 230 ml/kg/d and total calories 204 kcal/kg/d).

Ingredient	Volume (ml)		Calories (kcal)		Calories Percentage (%)	
	Fasting + PN	Oral feeding + PN	Fasting + PN	Oral feeding + PN	Fasting + PN	Oral feeding + PN
20% medium long-chain fat emulsion (1)	38	19	72,2	36,1	35	17.4
10% compound amino acids	88	44	34,8	17.4	17	8.9
30% glucose	80	40	97	48,5	48	24
3% sodium chloride	13	6.5				
10% Potassium chloride	3	1				
10% calcium gluconate	3	1				
Water-soluble vitamins (2)	1/2 ampoule	1/4 ampoule				
Fat- Soluble vitamins (3)	1/2 ampoule	1/4 ampoule				
Trace elements (4)	1	0.5				
Total	**230**	**115**	**204**	**102**		

Note (1) medium/long-chain fat emulsion (250 ml) composition: soybean oil 25 gr, medium chain triglycerides 25gr and lecithin 3gr Linoleic acid 13gr, α-Linolenic acid 1.5 g.
3 g egg phospholipids.
(2) Water-soluble vitamins composition: vitamin B 1 0.5 mg, vitamin B 2 0.7 mg, nicotinamide 8 mg, vitamin B 6 0.2 mg, pantothenic acid 3 mg, vitamin C 20 mg, biotin 12 μg, folic acid 80 μg, vitamin B 100 μg. (3) Fat soluble vitamins composition: vitamin A 50 μg (165 IU), vitamin D 20.25 μg (10 IU), vitamin E 0.455 μg (0.5 IU) and vitamin K 7.5 μg. (4) Trace elements: Chromic chloride 6 H_2O 5.33 μg/ml, Copper chloride 2 H_2O 0.34 mg/ml, Ferric chloride 6 H_2O 0.54 mg/ml, Manganese chloride 4 H_2O 99.0 μg/ml, Potassium iodide 16.6 μg/ml, Sodium fluoride 0.21 mg/ml, Sodium molybdate 2 H_2O 4.85 μg/ml, Sodium selenite anhydrous 6.90 μg/ml, Zinc chloride 1.36 mg/ml.

rabbits were subsequently anaesthetized and euthanized, and small intestine tissue and blood samples were collected.

Blood samples

Blood samples (4 ml on average) were collected from all rabbits by intracardiac injection using an injector on the precordium and transferred into tubes (Vacutainer; BD, Plymouth, UK) containing a gel. The tubes were centrifuged at 4,000 rpm for 7 min, and then serum samples were collected and stored at −80 °C until the biochemical analysis. Before the analysis, the samples were heated to 23 °C.

Biochemical analysis

Serum total antioxidant capacity (TAC) and total oxidant capacity (TOC) levels were determined using a spectrophotometer (Microplate reader, BioTek Synergy H_1, BioTek Instruments, Winooski, VT, USA) as previously described [13,14]. Insulin levels were determined by chemiluminescence using an autoanalyzer (Siemens Healthcare, Llanberis, UK). Glucose levels were measured using an autoanalyzer (Abbott Diagnostics, Abbott Park, IL, USA). Mean glucose levels were calculated as the average of blood glucose levels and previous peripheral blood glucose measurements.

Collection and preparation of small intestine tissue samples

Within 20 min of euthanasia, the rabbits' abdomens were incised, and their small intestines were removed in a single piece. All contents were then emptied out, and the intestines were washed with serum saline. They were subsequently separated from the vascular pedicle, and then their length from the pylorus to the ileocaecal junction was measured and recorded. Samples were then rinsed with serum saline and placed in 10% formalin for 24 h.

Histopathological procedures

Samples 3–3.5 cm long were taken from the intestine 20 cm distal to the pylorus [15]. Each sample was sliced to five to six pieces 0.3–0.5 cm thick, which were placed in phosphate-buffered saline (PBS) with 4% formaldehyde (pH 7.4) for 24 h [16]. After fixation, the samples were processed according to standard histological methods and embedded in paraffin blocks [15]. The blocks were then cut into sections 5 μm thick, dewaxed, and hydrated by using xylene and a series of alcohol concentrations. The sections were stained with haematoxylin and eosin (H&E) following standard procedures [2].

The H&E-stained sections were examined using an Eclipse Ni-U light microscope (Nikon Corp., Tokyo, Japan). A total of 50 villi and 50 crypts from each animal were measured using the image analysis functions of NIS-Elements Documentation 5.02 (Nikon Corp.). The length of the villi was measured from the top of the villus to the villus-crypt transition point (Fig. 1A and B). The depth of invagination between two villi was measured as the crypt depth (Fig. 1C and D) [17]. Paneth cells were used to identify the base of each crypt [17]. Morphological evaluation of apoptosis was performed. If one or more apoptotic bodies were present at the evaluated cell position, the cell was considered apoptotic (Fig. 2A) [17].

Immunohistochemical procedures

Tissue sections 5 μm thick were placed on adhesive slides and deparaffinized. The slides were then placed in citrate buffer (pH 7.6; Thermo Scientific, Fremont, CA, USA), and antigen retrieval was applied in a pressure cooker (Retriever 2100; Aptum, Southampton, UK) at 121 °C for 15 min. After cooling, the citrate buffer was removed, and PBS was added. The slides were washed with PBS at each step except between protein blocking and primer antibody application. The following

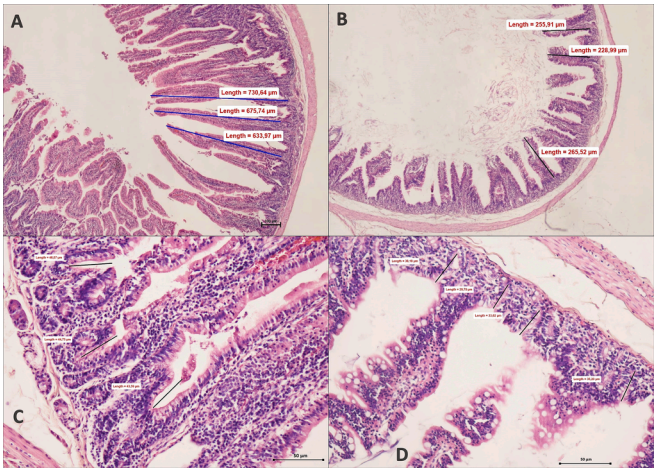

Fig. 1. A. Villus length measurement in a control group sample. H&E; 40× magnification. B. Villus length measurement in a fasting + PN group sample. H&E; 40× magnification. C. Crypt depth measurement in a control group sample. H&E; 100× magnification. D. Crypt depth measurement in a fasting + PN group sample. H&E; 100× magnification.

steps were applied at room temperature. A horseradish peroxidase kit (Thermo Scientific) for immunohistochemical staining was used according to the manufacturer's protocol. First, 3% hydrogen peroxide was applied for 10 min. Second, a protein-V blocking solution was applied for 5 min, followed by incubation with Anti-Caspase-3 primer antibody ([ABM1C12] ab208161, abcam, Cambridge, UK) dilution rate 1:300) for 1 h. Third, slides were incubated in biotinylated goat anti-polyvalent secondary antibody for 10 min. Then, streptavidin peroxidase was applied and incubated for 10 min. AEC chromogen (Thermo Scientific) was then applied and incubated for 15 min. Finally, the slides were immersed in distilled water, counterstained with Mayer's haematoxylin, and mounted. Analysis and imaging were then performed using an Eclipse Ni-U light microscope and NIS-Elements Documentation 5.02 (Nikon Corp.).

Apoptosis scoring and evaluation in sections stained with H&E and caspase-3

Apoptosis in sections stained with H&E was scored using an Eclipse Ni-U light microscope and NIS-Elements Documentation 5.02 (Nikon Corp.) with a x400 magnification. Whole longitudinal sections of villi and crypts where crypt lumina were completely visible were chosen. Apoptosis scoring was performed by two surgical pathologists blinded to the experimental data and each other's evaluations. Inter-pathologists variability was less than 5%. For the evaluation of apoptosis, whole cells within the epithelia of 50 half villi and half of the neighbouring crypts on the same side were counted, starting from the top of the villus to the base of the crypt. Cells containing apoptotic fragments were counted and recorded [17]. The ratio of apoptotic cells to the total cells in the epithelium was then calculated [16]. This ratio was recorded as an apoptosis score for each rabbit. For each rabbit, the average of the total scoring of the two pathologists was calculated and used for statistical analysis.

Scoring in sections stained with caspase-3 was performed using the same method. Positive cells were counted and recorded (Fig. 2B and C) [16]. The ratio of positive cells to the total cells in the epithelium was then calculated [16].

Transmission electron microscopy

A piece of tissue about 2 mm wide, 2 mm long, and 1 mm thick was removed from the distal end of each rabbit's tissue sample and washed

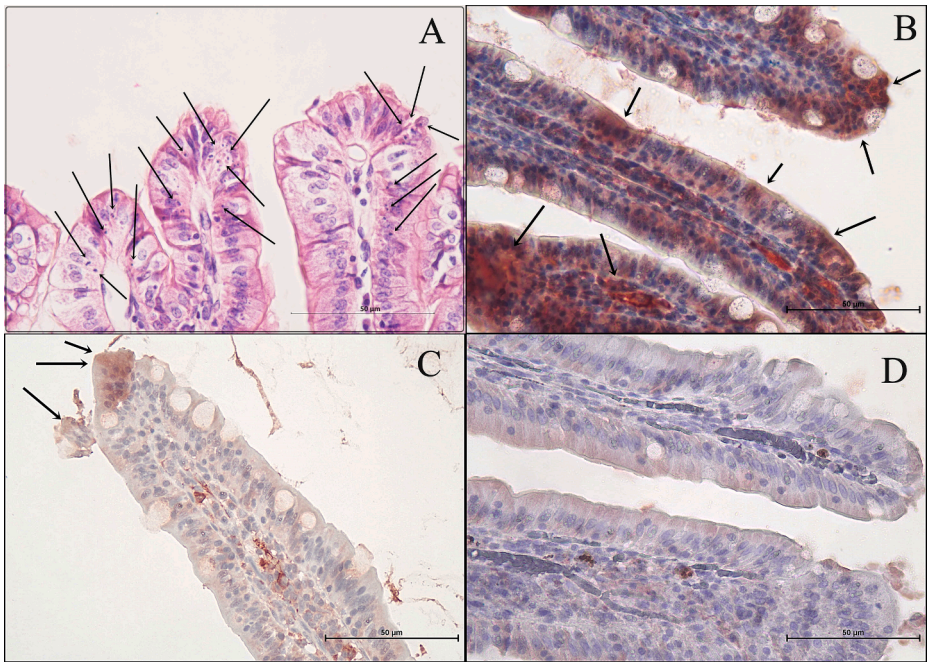

Fig. 2. A. Fasting + PN group villi with apoptotic bodies, in cells those have passed to apoptotic process (black arrows). H&E; 400× magnification. B. Increased caspase-3 expression in small intestine villi of the fasting + PN group (black arrows) 200× magnification. C. Caspase-3 expression also increased in the oral feeding + PN group, but the increase was not as significant as in the fasting + PN group. (Black arrows) 200× magnification. D. Decreased caspase-3 expression in small intestine villi in the control group. 200× magnification.

with serum saline. The obtained samples were then fixed in 2.5% glutaraldehyde buffered with 0.2 M of NaH_2PO_4 + $NaHPO_4$ (pH 7.4), followed by post-fixation in 1% OsO_4. The sections were contrasted with uranyl acetate and lead citrate. They were subsequently examined under a Libra 120 transmission electron microscope (Carl Zeiss NTS, Oberkochen, Germany) and photographed. Intra-cytoplasmic oedema, organelle degeneration, and apoptotic-looking nucleus structures with reduced diameters in heterochromatic structures were investigated.

Statistical analysis

The normality of data was evaluated using the Shapiro-Wilk test. The homogeneity of variance between groups was evaluated using Levene's test. For homogeneous group variances, one-way analysis of variance and Tukey's honest significant difference post-hoc test were used; otherwise, Welch's test and Tamhane's T2 post-hoc test were used. Before-after comparisons were performed using the paired-samples *t*-test. In all analyses, a two-sided value of $p < 0.05$ was considered statistically significant. Values were expressed as means and standard deviations. IBM SPSS Statistics version 22.0 (IBM Corp., Armonk, NY, USA) for Windows was used for the analyses.

Results

Weight changes

Table 2 shows the statistical analysis results of the weight changes in the four groups. The difference in weight change between the two PN groups and the control group was not statistically significant. The semi-starvation group showed a statistically significant decrease in weight.

Table 2
Statistical analysis of the change in weight of rabbits in study groups during the study period.

Groups	Weight before PN (g)	Weight after PN (g)	p-value
Control (n = 14)	3390,28 ± 107,52	3392,98 ± 119,29	0,931
Semi starvation (n = 14)	3349,54 ± 155,59	3183,84 ± 124,05	**<0,001**
Fasting + PN (n = 14)	3408,92 ± 106,22	3392,93 ± 85,73	0,226
Oral feeding + PN (n = 14)	3374,64 ± 108,58	3367,07 ± 137,65	0,631

Blood glucose and insulin levels and oxidative stress parameters

The mean blood sugar level of the fasting + PN group was significantly higher than those of the other groups. There were no statistically significant differences between the other three groups (Table 3).

The mean blood insulin level of the fasting + PN group was significantly lower than those of the other groups. There were no statistically significant differences between the other three groups (Table 3).

The mean blood TOC level of the fasting + PN group was significantly higher than those of the other groups. There were no statistically significant differences between the other three groups (Table 3).

The mean blood TAC levels of the fasting + PN and oral feeding + PN groups were significantly lower than those of the other two groups. The differences between the two PN groups and between the semi-starvation and control groups were not statistically significant (Table 3).

Table 3
Biochemical and oxidative stress parameters of the four groups.

Parameter	Control (n = 14)	Semi-starvation (n = 14)	Fasting + PN (n = 14)	Oral feeding + PN (n = 14)	*p*-value
Glucose (mg/dl)	106.43 ± 6.42^a	106.50 ± 6.30^a	308.07 ± 34.91^b	120.14 ± 24.94^a	**<0.001**
Insulin (units/ml)	3.74 ± 0.98^a	3.61 ± 1.06^a	1.41 ± 0.21^b	3.58 ± 1.25^a	**<0.001**
TOC (μmol H_2O_2 equiv./L)	7.80 ± 2.02^a	8.06 ± 1.90^a	36.95 ± 5.26^b	9.08 ± 2.08^a	**<0.001**
TAC (mmol Trolox equiv./L)	0.99 ± 0.06^a	0.98 ± 0.08^a	0.83 ± 0.08^b	0.87 ± 0.05^b	**<0.001**
OSI (mmol Trolox/ mmol H_2O_2)	7.87 ± 1.86^a	8.21 ± 1.79^{a,c}	44.86 ± 6.90^b	10.40 ± 2.45^c	**<0.001**

TOC: total oxidant capacity; TAC: total antioxidant capacity; OSI: oxidative stability index.
*The difference between the groups with different superscript letters are statistically significant.

The oxidative stability index (OSI) of the fasting + PN group was significantly higher than those of the other three groups. There were no statistically significant differences between the oral feeding + PN and semi-starvation groups or between the semi-starvation and control groups (Table 3).

Histopathological and immunohistochemical results

The statistical analysis results of the histopathological and morphological parameters of the four groups are shown in Table 4. There were no statistically significant differences in mean small intestine length between the four groups.

The mean small intestine villus lengths was significantly lower in the fasting + PN group than in the other three groups. The mean small intestine villus lengths in the semi-starvation and control groups were significantly greater than those of the two PN groups. The differences between the semi-starvation and control groups were not statistically significant (Table 4, Fig. 3A).

The mean small intestine crypt depths of the semi-starvation and control groups were significantly greater than that of the fasting + PN group. There were no statistically significant differences between the oral feeding + PN group and the other groups (Table 4, Fig. 3B).

The apoptosis score was significantly higher in the fasting + PN group than in the other three groups. Although the apoptosis score of the oral feeding + PN group was significantly higher than in the semi-starvation and control groups, it was still significantly lower than in the fasting + PN group (Table 4, Fig. 3C).

Caspase-3 expression was significantly higher in the fasting + PN group than in the other three groups. Although caspase-3 expression in the oral feeding + PN group was significantly higher than in the semi-starvation and control groups, it was still significantly lower than in the fasting + PN group (Table 4, Fig. 3D).

Transmission electron microscopy results

Transmission electron microscopic images of enterocytes in small intestine sections of rabbits in the control and semi-starvation groups in normal ultrastructure view are shown in Fig. 4A and B, respectively.

Widespread and severe intra-cytoplasmic oedema and organelle degeneration were observed in the small intestine sections of rabbits in the fasting + PN group. Apoptotic enterocytes characterized by heterochromatic/pyknotic-looking nuclei were also detected (Fig. 4C and D).

Mild intra-cytoplasmic oedema, organelle degeneration, and

Table 4
Histopathological and immunohistochemical parameters of small intestines in the four groups.

Parameter	Control (n = 14)	Semi-starvation (n = 14)	Fasting + PN (n = 14)	Oral feeding + PN (n = 14)	*p*-value
Mean small intestine length (cm)	307.69 ± 19.21	305.49 ± 18.97	295.44 ± 21.19	298.51 ± 17.44	0.347
Mean villus length (μm)	679.49 ± 32.22[a]	670.96 ± 35.32[a]	250.10 ± 17.24[b]	543.58 ± 57.74[c]	**<0.001**
Mean crypt depth (μm)	43.85 ± 2.59[a]	41.88 ± 3.06[a]	34.04 ± 3.02[b]	39.04 ± 7.12[a,b]	**<0.001**
Mean staining score (Caspase-3 expression)	0.01 ± 0.001[a]	0.021 ± 0.001[a]	0.76 ± 0.15[b]	0.07 ± 0.0 01[c]	**<0.001**
Mean apoptosis score	0.01 ± 0.009[a]	0.02 ± 0.008[a]	0.34 ± 0.7[b]	0.07 ± 0.001[c]	**<0.001**

*The difference between the groups with different superscript letters are statistically significant.

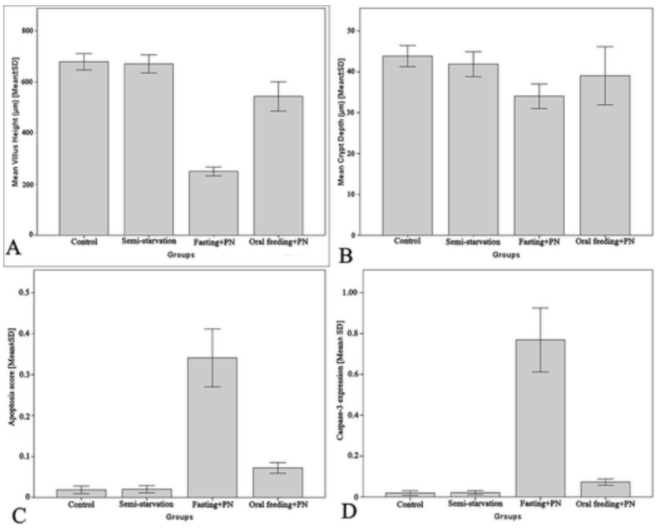

Fig. 3. Histopathological evaluation results of the four groups. A. Mean villus lengths. B. Mean crypt depths. C. Mean apoptosis scores. D. Mean caspase-3 expression.

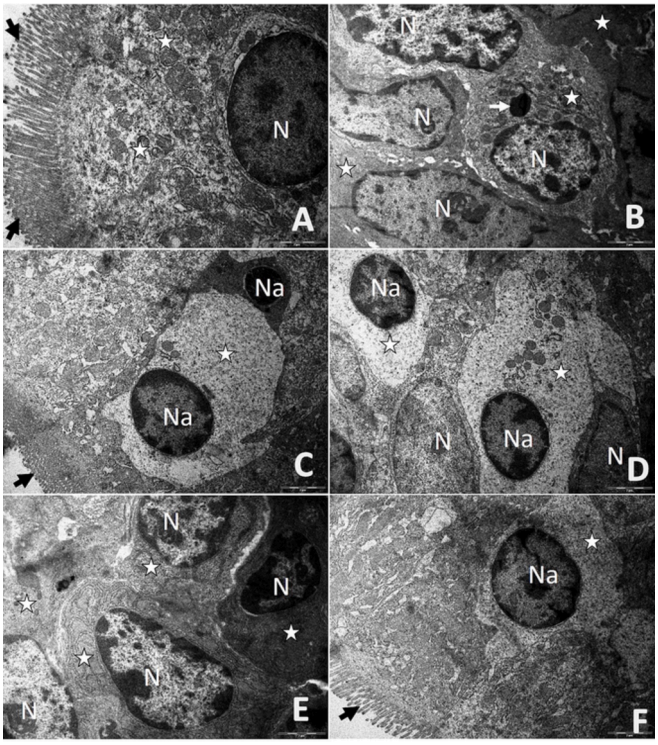

Fig. 4. A. Enterocyte nuclei (N), enterocyte cytoplasm (asterisk), and microvilli (arrow) in the control group. B. Enterocyte nuclei (N), enterocyte cytoplasm (asterisk), and lysosome (arrow) in the semi-starvation group. TEM 6300× magnification. C. Nuclei of apoptotic enterocytes (Na), intracytoplasmic oedema and organelle loss (asterisk), and microvilli (arrow) in the fasting + PN group. D. Enterocyte nuclei (N), nuclei of apoptotic enterocytes (Na), and intracytoplasmic oedema and organelle loss (asterisk) in the fasting + PN group. Uranyl acetate–lead citrate. TEM 6300× magnification. E. Enterocyte nuclei (N) and enterocyte cytoplasm (asterisk) in the oral feeding + PN group. F. Nuclei of apoptotic enterocytes (Na), intracytoplasmic oedema and organelle loss (asterisk), and microvilli (arrow) in the oral feeding + PN group. Uranyl acetate–lead citrate TEM 6300× magnification.

heterochromatic nuclei were observed in enterocytes of rabbits in the oral feeding + PN group. Apoptotic enterocytes were rarely observed (Fig. 4E and F).

Discussion

In this study, we investigated the destructive effects of the combination of PN and starvation on the small intestines of rabbits. The ultrastructural and histopathological analyses revealed a significant increase in apoptotic activity in the fasting + PN group, although the total small intestine length was not different from that of the control group. This severe damage not only affected the size of the villi and the depth of the crypts in the small intestines of the rabbits in this group but also severely damaged the nuclei and organelles of enterocytes. These changes may be the result of increased apoptotic activity.

Although minor ultra-structural changes were observed in the enterocytes of the oral feeding + PN group, triggering a moderate increase in apoptotic activity, this did not have destructive histopathological and morphological effects on the small intestines. The depth of the crypts did not decrease. However, there was a mildly decrease in the length of the villi in this group.

The weight loss observed in the semi-starvation group indicates systemic effects of starvation. Despite the weight loss, however, no negative effects were observed on the ultra-structural and histopathological structure of the small intestines of this group.

Peripheral and intravenous blood glucose measurements showed significant hyperglycaemia in the fasting + PN group. The glucose levels in the other three groups were normal. The fact that the oral feeding + PN group did not develop hyperglycaemia suggests that the combination of PN and starvation disrupts the mechanism that regulates blood sugar. Hyperglycaemia, defined as a randomly measured blood sugar level above 200 mg/dl [18], is a known adverse effect of PN [19–21]. A previous study found that more than 50% of patients receiving PN developed hyperglycaemia [21]. The pathogenesis of hyperglycaemia during PN is complex and has been associated, among others, with the administration of high-concentration dextrose solutions, decreased use of peripheral glucose, and blood glucose dysregulation [18,21–23].

Hyperglycaemia has been reported to cause oxidative stress [24]. Parenteral nutrition has also been found to cause oxidative stress by reducing antioxidant levels and increasing oxidative injury products [25,26]. Our findings are consistent with our previous study, where we reported that the combination of PN and starvation leads to oxidative stress and that hyperglycaemia is linked to this process [11]. Both studies lead us to speculate that low insulin levels may play an important role in this pathogenesis. The significantly lower insulin levels that we observed in the fasting + PN group compared to the other groups support this hypothesis. We speculate that the combination of PN and starvation is responsible for the low levels of insulin, which plays an important role in regulating blood sugar.

The literature suggests important associations between parenteral nutrition, tissue damage (in the heart and liver), hyperglycaemia, and oxidative stress [11, 27, and 28]. Pahwa et al. reported that oxidative stress, combined with hyperglycaemia, causes cardiac, microvascular, and macrovascular inflammation by activating Toll-like receptors in circulating monocytes [28], which damage microvascular and macrovascular endothelial cells and cardiomyocytes [28]. Moreover, activated Toll-like receptors activate Interleukin-1 and Interleukin-8, which cause systemic inflammation, resulting in cell and tissue damage in various parts of the body [29]. Cell damage leads to increased levels of free oxygen radicals in circulation [29]. This increase in TOC results in a decrease in TAC and an increase in systemic oxidative stress [30]. In a healthy body, free radicals, which are the result of anabolism and catabolism processes, are strictly controlled, and a balance between free radical production and the antioxidant mechanism is maintained. A disruption of this balance in favour of free radicals leads to oxidative stress [31]. Yarıbeygi et al. reported that hyperglycaemia causes oxidative stress and elucidated the molecular mechanism of this pathway [31]. In line with the literature, we found that the TOC and OSI, important indicators of oxidative stress, were significantly higher, and the TAC was significantly lower in the fasting + PN group than in the other groups. Although the TAC also decreased in the oral feeding + PN group, we did not observe significantly high OSI and TOC values. This suggests that PN causes an increase in oxidative stress but does not reach devastating levels unless combined with starvation.

We also observed severe apoptosis in small intestine tissue samples of the fasting + PN group. Apoptosis is programmed cell death that is normally not harmful to the functions of biological organisms [32]. Increased apoptosis can cause atrophy in the tissue, causing impaired function [32]. Previous studies have suggested that hyperglycaemia and oxidative stress may cause increased apoptosis [33–36]. Parenteral nutrition has been shown to cause villus atrophy through apoptosis in the alimentary tract [37] via two different pathways. One is the Fas/FasL pathway, which activates intestinal intraepithelial lymphocytes, and the other is neutrophil activation [38]. An increase in apoptosis in a tissue can be determined by an increase in caspase activation [39]. In our study, caspase-3 expression analysis showed that although apoptosis increased in small intestine tissue samples of the oral feeding + PN group, it was not as destructive as in the fasting + PN group.

Although several studies have reported that systemic oxidative stress, hyperglycaemia, and apoptosis are closely related [26–28,30,31,33–35], no previous studies have examined how the combination of PN and starvation turns this relation into a destructive force in small intestine tissue. The results of our study suggest that PN leads to hyperglycaemia by disrupting the blood sugar regulation system, increasing oxidative stress and apoptosis, which exerts a devastating effect on small intestine tissue, leading to villus and crypt atrophy. Further studies are needed to confirm this mechanism.

In studies investigating the effects of starvation combined with PN on the intestines, it has been claimed that starvation is actually the major cause of these effects not PN itself [40,41]. In these studies, it has been claimed that starvation combined with PN reduces intestinal epithelial growth factors, resulting in an increase in intestinal apoptosis and deterioration in epithelial barrier function [40,41]. This situation has been claimed to cause bacterial translocation. Blood glucose and insulin levels were not investigated in these studies. In addition, there was no group of pure hunger in these studies. In our study, we think that strong systemic oxidative stress emerging due to hyperglycaemia-hypoinsulinemia is the cause of the increased apoptosis in intestinal epithelium in the group of starvation combined with PN. In fact, the findings of our study do not contradict these studies, but unlike them, we think that hyperglycaemia is the primer culprit agent, not the starvation.

Our study has its limitations. Our study is a study of experimental animals. The findings and results of this study may not be exactly the same in humans. In this study, there is no pure starvation group without feeding in any way. This study does not explain which of the components in the PN is responsible for the negative effects it has on the small intestines.

We believe that the gastro-intestinal system is as if it is the customs gate of the body. Nutrients that do not pass through customs, even if they enter the body illegally (parenteral nutrition), are not able to reach the cell in need properly. As a result, excessive accumulation of nutrients occurs in some parts of the body (hyperglycaemia), while nutrients will not reach some parts of the body those need it. In conclusion, parenteral nutrition combined with starvation can lead to destructive villus and crypt atrophy due to hyperglycaemia with hypoinsulinemia, systemic oxidative stress, and apoptosis in small intestine tissue. The addition of enteral nutrition to PN may reduce these destructive effects.

Funding

This work was supported by Inonu University's Scientific Research Project Coordination Unit [project code TSA-2020-2284].

Declaration of competing interests

The authors declare that they have no known competing financial interests or personal relationships that could have appeared to influence the work reported in this paper.

References

[1] Demircan M, Gürünlüoğlu K, Karaman A, Mızrak B. Damaging effects of total parenteral nutrition Formula on vascular endothelium. J pediatr Gastroenterol Nutr 2015;61(4):464–8.
[2] Teitelbaum DH, Coran AG. Nutritional support. In Grosfeld JL, O'Neill JA, Fonkalsrud EW, Coran AG editors. Textbook of pediatric surgery. 6. Ed. Philadelphia: 2006. Vol 1, Chap.12: pp: 194-220.
[3] Holden WD, Kreiger H, Levey S. The effects of nutrition on nitrogen metabolism in the surgical patient. Ann Surg 1957;146:563–70.
[4] Dudrick SJ. Early developments and clinical applications of total parenteral nutrition. J Parenter Enteral Nutr 2003;27(4):291–9.
[5] Ward N. Nutrition support to patients undergoing gastrointestinal surgery. Nutr J 2003;2:1–5.
[6] Wang H, Khaoustov IV, Krishnan B, Cai W, Stoll B, Burring DG, et al. Total parenteral nutrition induces liver steatosis and apoptosis in neonatal piglets. J Nutr 2006;136:2547–52.
[7] Demircan M, Ergün O, Coker C, Yılmaz F, Avanoğlu S, Ozok G. Aluminium in total parenteral nutrition solutions produces portal inflammation in rats. J Pediatr Gastroenterol Nutr 1998;26(3):274–8.
[8] Zhu X, Zhang X, Yu L, Xu Y, Feng X, Wang J. Hepatic overexpression of GRP94 in a rabbit model of parenteral nutrition-associated liver disease. Gastroenterol Res Pract 2015;2015:1–8.
[9] Fernandes PC, Dolinger EJ, Abdallah VO, Resende DS, Gontijo Filho PP, Brito D. Late onset sepsis and intestinal bacterial colonization in very low birth infants receiving long-term parenteral nutrition. Rev Soc Bras Med Trop 2011;44(4): 447–50.
[10] Buchman AL, Neely M, Grossie VB Jr, Truonq L, Lykissa E, Ahn C. Organ heavy-metal accumulation during parenteral nutrition is associated with pathologic abnormalities in rats. Nutrition. 2001; 17(7): 600-6.
[11] Gürünlüoğlu K, Gül M, Koçbıyık A, Koç A, Üremiş N, Gürünlüoğlu S, et al. Investigation of the cardiotoxic effects of parenteral nutrition in rabbits. J Pediatr Surg 2020;55(3):465–74.
[12] Teitelbaum DH. Parenteral nutrition-associated cholestazis. Curr Opin Pediatr 1997;9:270–5.
[13] Erel O. A novel automated direct measurement method for total antioxidant capacity using a new generation, more stable ABTS radical cation. Clin Biochem 2004;37(4):277–85.
[14] Erel O. A new automated colorimetric method for measuring total oxidant status. Clin Biochem 2005;38(12):1103–11.
[15] Makovicky P, Tumova E, Volek Z, Makovicky P, Vodicka P. Histological aspects of the small intestine under variable feed restriction: The effects of short and intense restriction on a growing rabbit model. Exp Ther Med 2014;8:1623–7.
[16] Tanaka K, Hashimoto H, Tachibana T, Ishikawa H, Ohki T. Apoptosis in the small intestine of neonatal rat using blue light-emitting diode devices and conventional halogen-quartz devices in phototherapy. Pediatr Surg Int 2008;24(7):837–42.
[17] Marshman E, Ottewel PD, Potten CS, Watson AJM. Caspase activation during spontaneous and radiation-induced apoptosis in the murine intestine. J Pathol 2001;195(3):285–92.
[18] Cook CB, Kongable GL, Potter DJ, Abad VJ, Leija DE, Anderson M. Inpatient glucose control: a glycemic survey of 126 U.S. hospitals. J Hospital Med 2009;4: E7–14.
[19] Rosmarin DK, Wardlaw GM, Mirtallo J. Hyperglycemia associated with high, continuous infusion rates of total parenteral nutrition dextrose. Nutr Clin Pract 1996;11(4):151–6.
[20] Pleva M, Mirtallo JM, Steinberg SM. Hyperglycemic events in non-intensive care unit patients receiving parenteral nutrition. Nutr Clin Pract 2009;24(5):626–34.
[21] Gosmanov AR, Umpierrez GE. Management of hyperglycemia during enteral and parenteral nutrition therapy. Curr Diab Rep 2013;13(1):155–62.
[22] Hsu C. Glycemic control in critically ill patients. World J Crit Care Med 2012;1(1): 155–62.
[23] McCulloch A, Bansiya V, Woodward JM. Addition of insulin to parenteral nutrition for control of hyperglycemia. JPEN J Parenter Enteral Nutr 2018;42(5):846–54.
[24] Luck K, Schramm-Luc A, Guzik TJ, Mikolajczyk TP. Oxidative stress and inflammatory markers in prediabetes and diabetes. J Physiol Pharmacol 2019;70 (6):809–24.
[25] Matilla B, Ortíz J, González P, García-Díez F, Jorquera F, Culebras JM, et al. Effects of parenteral nutrition supplemented with glutamine or glutamine dipeptides on liver antioxidant and detoxication systems in rats. Nutrition 2000;16(2):125–8.
[26] Chessex P, Lavoie J-C, Rouleau T, Brochu P, St-Louis P, Lévy E, et al. Photooxidation of parenteral multivitamins induces hepatic steatosis in a neonatal guinea pig model of intravenous nutrition. Pediatr Res 2002;52(6):958–63.
[27] Cai W, Wu J, Hong Li, Xu Y, Tang Q, Shi C. Oxidative injury and hepatocyte apoptosis in total parenteral nutrition-associated liver dysfunction. J Ped Surg 2006;41(10):1663–8.
[28] Pahwa R, Jialal I. Hyperglycemia induces Toll-Like receptor activity through increased oxidative stress. Metab Syndr Relat Disord 2016;14(5):239–41.
[29] Toliver-Kinsky T, Kobayashi M, Suzuki F, Sherwood ER. The systemic inflammatory response syndrome. In: Herndon DN, editor. Total burn care. 5th ed. Philadelphia: Elsevier; 2018. p. 205–20.
[30] Gürünlüoğlu K, Demircan M, Taşçı A, Üremiş MM, Türköz Y, Bağ HG, et al. The effects of two different burn dressings on serum oxidative stress indicators in children with partial burn. J Burn Care Res.2019; 40(3): 444-40.
[31] Yarıbeygi H, Atkin SL, Sahebkar A. A review of the molecular mechanism of hyperglycemia-induced free radical generation leading to oxidative stresa. J Cell Physiol 2019;234(2):1300–12.
[32] Wildhaber BE, Lynn KN, Yang H, Teitelbaum DH. Total parenteral nutrition-induced apoptosis in mouse intestinal epithelium: regulation by the Bcl-2 protein family. Pediatr Surg Int 2002;18(7):570–5.
[33] Chen Z, Guo H, Lu Z, Sun K, Jin Q. Hyperglycemia aggravates spinal cord injury through endoplasmic reticulum stress mediated neuronal apoptosis, gliosis and activation. Biomed Phemacother 2019;112:108672.
[34] Jancso Z, Bodi N, Borsos B, Fekete E, Hermesz E. Gut region-specific accumulation of reactive oxygen species leads to regionally distinct activation of antioxidant and apoptotic marker molecules in rats with STZ-induced diabetes. Biochem Cell Biol 2015;62:125–31.
[35] Diaz de Barboza G, Guizzardi S, Moine L, Tolosa de Talamoni N. Oxidative stress, antioxidants and intestinal calcium absorption. World J Gastroenterol 2017;23 (16):2841–53.
[36] Ray PD, Huang BW, Tsuji Y. Reactive oxygen species (ROS) homeostasis and redox regulation in cellular signaling. Cell Signal 2012;24(5):981–90.
[37] Yang H, Fan Y, Teitebaum DH. Interferon-gamma mediates epithelial cell apoptosis through a Fas/FasL interaction in Mouse model of totalparenteral nutrition (TPN). Gastroenterology 2001;120:A676.
[38] Tarnawski AS, Szabo I. Apoptosis-programmed cell death and its relevance to gastrointestinal epithelium: survival signal from the matrix. Gastroenterology 2001;120(1):294–8.
[39] Demirtas L, Guclu A, Erdur FM, Akbas EM, Ozcicek A, Onk D, et al. Apoptosis, autophagy & endoplasmic reticulum stress in diabetes mellitus. Indian J Med Res 2016;144(4):515–24.
[40] Wildhaber BE, Yang H, Spencer AU, Drongowski RA, Teitelbaum DHJ. Lack of enteral nutrition–effects on the intestinal immune system. Surg Res 2005;123(1): 8–16.
[41] Feng Y, Ralls MW, Xiao W, Miyasaka E, Herman RS, Teitelbaum DH. Loss of enteral nutrition in a mouse model results in intestinal epithelial barrier dysfunction. Ann N Y Acad Sci 2012;1258:71–7.